UNIVERSITY OF TORONTO SPINE PROGRAM

Journal Club

Webinar

SPORTS AND SPINE SURGERY

December 7, 2020

6:00 PM EST

Registration link Here

Surgery
UNIVERSITY OF TORONTO
Spine Program

P	CONTENT
3	AGENDA
4	SPEAKERS
9	**READING (APPENDIX)**

Accreditation:

This educational event is a self-approved group learning activity (Section 1) as defined by the Maintenance of Certification Program of the Royal College of Physicians and Surgeons of Canada

AGENDA

6:00 PM	Welocme Remarks (**Professpr Michael Fehlings & Professor Albert Yee)**
6:05 PM	Introduction (Dr. Jefferson Wilson) **Moderator**
6:10 PM	**U of T Spine Fellow Presntations:** **Drs. Kelechi Eseonu (Lead); Peter Proemmel; Dhawi Al-Otaibi; and Manuel Fuetsch.**

Articles:

Sports related spinal injuries:

1. The Management of Acute Lumbar Stress Reactions of the Pedicle and Pars in Professional Athletes Playing Collision Sports.
   Presenter: Dr P Proemmel

2. ProDisc-C Total Disc Replacement Versus Anterior Cervical Discectomy and Fusion for Single-Level Symptomatic Cervical Disc Disease: Seven-Year Follow-up of the Prospective Randomized U.S. Food and Drug Administration Investigational Device Exemption Study.
   Presenter: Dr M Fuetsch

Return-to-play after spine surgery:

3. Updated Return-to-Play Recommendations for Collision Athletes After Cervical Spine Injury: A Modified Delphi Consensus Study With the Cervical Spine Research Society.
   Presenter: Dr D Al-Otaibi

4. Return-to-Play Recommendations After Cervical, Thoracic, and Lumbar Spine Injuries: A Comprehensive Review.
   Presenter: Dr K eseonu

7:15 PM	**Discussion**
7:25-7:30 PM	Wrap up

Co-Directors

U of T SPINE PROGRAM CO-DIRECTORS

Dr. Michael Fehlings is a Professor of Neurosurgery, Co-Director of the Spine Program and Vice Chairman (Research) in the Department of Surgery at the University of Toronto. He holds the Halbert Chair in Neural Repair and Regeneration and combines an active clinical practice in complex spinal surgery at the Toronto Western Hospital with a translationally oriented research program focused on discovering novel treatments for the injured brain and spinal cord. He has authored over 950 peer-reviewed articles (h-index 94) chiefly in the area of central nervous system injury and complex spinal surgery. His work has been featured in Nature, Nature Neuroscience, Science Translational Medicine, Nature Reviews Neurology, JAMA, Lancet Neurology, and the New England Journal of Medicine. Dr. Fehlings has held a number of prominent leadership roles, including current President of the International Neurotrauma Society, the Chair of the AO Foundation Clinical Investigation and Documentation Advisory Committee, past Chair of the AOSpine International Spinal Cord Injury Knowledge Forum, past President of the Cervical Spine Research Society, and leader of several international clinical research trials. Dr. Fehlings is a Fellow of the Royal Society (Canada) and a Fellow of the Canadian Academy of Health Sciences. He has received numerous international recognitions including the Royal College Gold Medal, Olivecrona Award, Ryman Prize, Magnus Medal in Neurosurgery and the Jonas Salk Award.

Dr. Albert Yee is the Holland Bone and Joint Program Chief and the Head of the Division of Orthopaedic Surgery at Sunnybrook Health Sciences Centre, where he holds the Marvin Tile Chair in Orthopaedic Surgery. Dr. Yee is an Orthopaedic Spine Surgeon at Sunnybrook Health Sciences Centre, an Associate Scientist (Physical Sciences Platform) at Sunnybrook Research Institute and a Consultant in Surgical Oncology, Bone Metastasis Clinic, Odette Cancer Centre. He is a Full Professor at the University of Toronto in the Institute of Medical Sciences with a cross appointment in the Institute of Biomaterials and Biomedical Engineering. He is the Vice Chair of Research in the Division of Orthopaedic Surgery and Co-Director of the University of Toronto's Department of Surgery Spine Program. Dr. Yee is the Past President of the Canadian Orthopaedic Research Society, President of the Canadian Spine

Society and Co-Chair of Bone & Joint Canada. He is the Canadian Lead for the Young Investigators Initiative (YII) of Bone & Joint Canada, and the US Bone & Joint Initiative, a grant mentorship and career development program. Dr. Yee has over 100 peer reviewed publications and has received academic honours including the American British Canadian (ABC) International Travelling Fellowship (American Orthopaedic Association / Canadian Orthopaedic Association, 2013), the Charles H. Tator Surgeon-Scientist Mentoring Award (2012), and the Canadian Orthopaedic Foundation J. Edouard Samson Award (2011). Dr. Yee's laboratory focuses on translational orthopaedic research utilizing pre-clinical surgical models to evaluate novel minimally invasive vertebral metastatic therapies (e.g. Photodynamic Therapy, Radiofrequency Ablation). His work has led to first in human clinical trials and FDA approval with commercialization of new minimally invasive spine technology. He has interest in understanding mechanisms of disease in cancer invasiveness to bone with an aim towards identifying potential new promising therapeutic targets.

SESSION HOST & SPEAKERS

Dr. Jefferson Wilson entered the neurosurgery program at University of Toronto after completing his MD at the University of Saskatchewan in 2007. During residency he earned a PhD through IMS and the Surgeon Scientist Program under the mentorship of Michael Fehlings and Abhaya Kulkarni with his research focused on the epidemiology and clinical epidemiology of traumatic spinal cord injury. Jeff's research has been funded by multiple grants from the Christopher and Dana Reeve Foundation, Cervical Spine Research Society and the Ontario Neurotrauma Foundation; further, he has been the recipient of numerous prestigious awards including: the K.G. McKenzie Prize from the Canadian Federation of Neurological Sciences, the Synthes Spinal Cord Injury Award from the American Association of Neurological Surgeon and the Shafie S. Fazel Outstanding Resident Surgeon and Investigator Award from the U of T Department of Surgery. After obtaining his FRCSC in neurosurgery in 2015, Jeff undertook a combined neurosurgery orthopedic fellowship in complex spine surgery at Thomas Jefferson University in Philadelphia, PA under the mentorship of James Harrop and Alex Vaccaro. Jeff returns to Toronto as a Surgeon Scientist at St. Michael's Hospital with clinical focus on the full spectrum of spinal disorders. From a research perspective, he is primarily interested in topics related to the epidemiology and clinical epidemiology of spinal trauma and spinal cord injury. Currently he serves as the Deputy Editor of the journal Clinical Spine Surgery.

U OF T CITYWIDE SPINE FELLOWS / TRAINEES

Dr. Kelechi Eseonu completed his primary medical qualification at the University of Edinburgh with an undergraduate degree in Genetics. This was followed by a Masters degrees in musculoskeletal sciences from the University of Oxford and Health Economics, Management and Policy from the London School of Economics. He is currently undertaking a year of fellowship training in Spinal surgery and trauma at St Michaels hospital.

Dr. Peter Prömmel completed his medical school at the University of Göttingen, Germany, followed by his neurosurgical residency at the University Hospital Zürich in Switzerland. He is an attending neurosurgeon at the Cantonal Hospital of St. Gallen, Switzerland, and he is currently undertaking a year of fellowship training at St. Michal's Hospital with focus on Complex Spine Surgery.

Dr. Dhawi Al-Otaibi completed his medical school at King Saud University and his Saudi Neurosurgery Board at King Fahad Medical City. Dr Al-Otaibi is currently doing complex spine surgery fellowship at Saint Michael's Hospital.

Dr. Manuel Fuetsch completed medical school in Innsbruck, Austria followed by residency at the University of Munich, Germany. Neurosurgical board certification in 2017. He is currently in his first year fellowship at Saint Michael's Hospital with a clinical focus on complex spine surgery. Having graduated in health business adminstration his additional interests lie in socio-economic impacts of different clinical practise approaches.

https://surgery.utoronto.ca/spine-program

UCFcOQ5s7ksDD73lJPnsD4kA

@UofTSpine

/UofTSpine

uoft.spine@utoronto.ca

(416) 978 8468

Surgery
UNIVERSITY OF TORONTO
Spine Program

Contact:

Nadia Jaber
Program Coordinator
email: uoft.spine@utoronto.ca
Tel: (416)978 8468
Room #: 503, 5th Floor Stewart Building
149 College St Toronto, ON, M5T 1P5

Articles

The Management of Acute Lumbar Stress Reactions of the Pedicle and Pars in Professional Athletes Playing Collision Sports

Alexander R. Vaccaro IV, BS, Srikanth N. Divi, MD, Christopher K. Kepler, MD, MBA, Gregory D. Schroeder, MD, Andrew C. Hecht, MD, Andrew B. Dossett, MD, Robert G. Watkins IV, MD, Robert G. Watkins III, MD, Shireen Mansoori, DPT, Jerome Reid, MSc, and Alexander R. Vaccaro, MD, PhD, MBA

Abstract: Acute stress reactions in the lumbar spine most commonly occur in athletes at the pars interarticularis followed by the pedicle. These reactions occur as a result of repetitive microtrauma from supraphysiological loads applied to the lumbar spine. Characteristic motions such as trunk extension and twisting are also thought to play a role and may be sport-specific. Other risk factors include increased lumbar lordosis, hamstring and thoracolumbar fascia tightness, and abdominal weakness. On physical examination, pain is typically reproduced with lumbar hyperextension. Currently, magnetic resonance imaging or nuclear imaging remain the most sensitive imaging modalities for identifying acute lesions. In the elite athlete, management of these conditions can be challenging, particularly in those playing collision sports such as American football, hockey, or rugby. Nonoperative treatment is the treatment of choice with rehabilitation programs focused on pain-free positioning and progressive strengthening. Operative treatment is rare, but may be warranted for patients symptomatic for >12 months. Specialized diagnosis protocols as well as treatment and return to play guidelines from 4 physicians treating elite athletes playing collision sports are presented and reviewed.

Key Words: spondylolysis, pars fracture, pars, pediculolysis, pedicle stress fracture, contact athlete, contact sports, collision sports

(*Clin Spine Surg* 2020;00:000–000)

Received for publication April 24, 2019; accepted August 19, 2020.
From the Department of Orthopaedic Surgery, Rothman Orthopaedic Institute at Thomas Jefferson University, Philadelphia, PA.
Dr Schroeder has received funds to travel from AO Spine and Medtronic. Dr Vaccaro has consulted or has done independent contracting for DePuy, Medtronic, Stryker Spine, Globus, Stout Medical, Gerson Lehrman Group, Guidepoint Global, Medacorp, Innovative Surgical Design, Orthobullets, Ellipse, and Vertex. He has also served on the scientific advisory board/board of directors/committees for Flagship Surgical, AO Spine, Innovative Surgical Design, and Association of Collaborative Spine Research. Dr Vaccaro has received royalty payments from Medtronic, Stryker Spine, Globus, Aesculap, Thieme, Jaypee, Elsevier, and Taylor Francis/Hodder and Stoughton. He has stock/stock option ownership interests in Replication Medica, Globus, Paradigm Spine, Stout Medical, Progressive Spinal Technologies, Advanced Spinal Intellectual Properties, Spine Medica, Computational Biodynamics, Spinology, In Vivo, Flagship Surgical, Cytonics, Bonovo Orthopaedics, Electrocore, Gamma Spine, Location Based Intelligence, FlowPharma, R.S.I., Rothman Institute and Related Properties, Innovative Surgical Design, and Avaz Surgical. He has also served as deputy editor/editor of Spine. In addition, Dr Vaccaro has also provided expert testimony. He has also served as deputy editor/editor of Clinical Spine Surgery. The remaining authors declare no conflict of interest.
Reprints: Srikanth N. Divi, MD, Department of Orthopaedic Surgery, Rothman Orthopaedic Institute at Thomas Jefferson University, 125 South 9th Street, Suite 1000, Philadelphia, PA 19107 (e-mail: srikanth.divi@gmail.com).
Copyright © 2020 Wolters Kluwer Health, Inc. All rights reserved.

Back pain is extremely common in competitive athletes, with an estimated prevalence of up to 30%.[1] In professional athletes, low back pain is one of the most common causes of lost playing time.[2] While most occurrences of back pain in athletes are benign sprains or strains with a self-limited time course, particularly close attention should be paid to athletes that are involved in collision sports where violent contact between players can occur, transferring large forces through the lumbar spine. Contact sports are typically defined as those that require the use of significant physical contact between athletes during play. With increasing participation and scrutiny of youth in these types of sports, the American Academy of Pediatrics created further subdivisions of sports into collision, contact, and limited-contact sports. According to their definition, collision sports (eg, American football, rugby) involves athletes purposely hitting or colliding with each other or inanimate objects with significant force.[3] In contact sports (eg, basketball, soccer), athletes routinely make contact with each other but with less force than in collision sports. In limited-contact sports (eg, golf, tennis), contact with other athletes or inanimate objects is infrequent. With the use of a large amount of force combined with specific movements in collision sports, repetitive microtrauma can occur and lead to increased stress concentration in susceptible regions. Specifically, in the lumbar spine, these can manifest as acute stress reactions in the pedicle and more commonly in the pars interarticularis.

Spondylolysis refers to a stress reaction of the pars interarticularis in the lumbar spine and is a common cause

Copyright © 2020 Wolters Kluwer Health, Inc. Unauthorized reproduction of this article is prohibited.

of pain in the adolescent population, especially in athletes engaged in strenuous, repetitive motions. With continued trauma, this stress reaction can progress to a bony defect which disrupts the posterior integrity of the neural arch and potentially allow forward slippage of the cephalad vertebra. Although less common than the pars, stress reactions may also occur in the lumbar pedicle, but require similar treatment and management. These conditions have been described extensively in skeletally immature patients, however, there is a lack of literature regarding diagnostic and treatment guidelines for adult athletes, specifically patients involved in collision sports such as American football, rugby, hockey, or wrestling. The purpose of this focused review is to briefly summarize the available literature on the epidemiology, diagnosis, and management of acute lumbar stress reactions of the pars and pedicle in professional athletes playing collision sports, such as American football and rugby, and to formulate recommendations for care and return to play.

PATHOPHYSIOLOGY

Wiltse first theorized that spondylolysis was the result of repetitive loads to the pars interarticularis, particularly with lumbar hyperextension and trunk rotation, resulting in a fatigue fracture rather than the result of one acute traumatic episode.[4] Because of the presence of numerous ossification centers in the posterior elements, and the fact that full maturation of the bony pars does not occur until approximately the age of 25, this leaves this region particularly susceptible to injury.[5] Biomechanical studies involving lumbar spine loading support this theory. Stress fractures are most commonly seen at the L5 level, likely because the greatest stresses in flexion and extension are found to occur at the L5–S1 junction as the mobile lumbar spine transitions to the relatively stiff sacrum, with particularly increased concentration of forces in the pars region.[6,7] In addition, the sagittal orientation of the L5–S1 facet articulation may increase stresses on the L5 lamina during lateral movements. In a cadaveric study applying cyclical loading to the inferior articular process in lumbar vertebrae, characteristic fractures were found in the pars region in 74% of specimens.[8] While stress reactions of the pedicle are less common, this same study showed that 6.8% of specimens also showed evidence of fatigue fractures in the pedicles, making it the next most common site of structural failure. Existing reports in the literature suggest that unilateral spondylolysis commonly leads to increased stress at the contralateral pedicle, placing it at risk for fatigue fracture.[9–15] In a different cadaveric study, increased cross-sectional area in the cortical bone may be protective against the increased stress experienced by the pars, suggesting a possible genetic predisposition.[16] Studies with radiographs analyzing newborns and adults who had never walked have found no cases of spondylolysis, indicating that weight-bearing is a significant contributor in combination with a multifactorial etiology.[17,18] Last, clinicians should be aware that spondylolysis can exist at >1 level at the same time and they may not be at same stages of healing. For example, an athlete could have an acute defect at one level and a chronic defect at another, presenting a challenging clinical entity.

Physical risk factors associated development of lumbar stress reactions include increased lumbar lordosis, iliopsoas and hamstring inflexibility, tight thoracolumbar fascia, abdominal weakness, and thoracic kyphosis.[5] Muscular tightness in adolescents undergoing rapid growth, along with a developing and fragile lamina, may contribute to the development of stress reactions. The presence of these risk factors in combination with repetitive sport-specific movements involving trunk extension and rotation places athletes at higher risk. Debnath et al[19] classified sports based on 4 major biomechanical movements in noncontact athletes: trunk twisting, kicking, throwing, and lifting. The authors found increased rates of pedicle and pars stress reactions in kicking and trunk twisting sports.

McCleary and Congeni[5] described 3 types of athletes presenting with spondylolysis: a hyperlordotic female athlete with increase range of motion and flexibility such as a gymnast; a muscular male athlete with decreased flexibility and tight paraspinal musculature; and a novice male or female athlete with poor trunk strength and flexibility who is exposed to repetitive stresses. Athletes involved in collision sports, such as American football and rugby, generally fit the second type of athlete described above and are constantly exposed to repeated strenuous axial loading and hyperextension moments that concentrate increase stress to the lumbar spine. Ferguson et al[20] theorized that interior linemen were particularly susceptible to lower lumbar injuries due to forceful collisions from a 3-point stance where the lumbar spine goes from a position of flexion to hyperextension, causing significant shearing forces at the facet joints and leading to a possible fracture at the pars interarticularis.

EPIDEMIOLOGY

Spondylolysis has been reported to have a prevalence ranging from 3% to 6% in the adult population, with increased rates among white males.[21] It is thought to form in early childhood, increase in incidence during adolescence, and stabilize during adulthood with no significant changes in rates in adults over age 20.[21] In fact, in a study of adolescent and adult athletes presenting with back pain, Micheli and Wood[22] found a significantly higher rate of spondylolysis in adolescents than adults (47% vs. 5%). The vast majority of these defects occur at L5 (71%–95%), followed by the L4 level (5%–23%).[23,24] Spondylolysis may occur at other levels but is generally much less common. Initially, these defects are painless and are unnoticed but may become painful with increased activity.

Overall rates of spondylolysis in competitive athletes have been reported to be ~7%–8%, therefore these rates are not much higher than the general population. However, in collision sports and sports involving increased

Copyright © 2020 Wolters Kluwer Health, Inc. All rights reserved.

Copyright © 2020 Wolters Kluwer Health, Inc. Unauthorized reproduction of this article is prohibited.

stress and load transfer to the lumbar spine such as gymnastics, weightlifting, wrestling, and American football, these rates are thought to be much greater with an estimated prevalence of up to 20%–30%.[2,5,25,26] Sex appears to be a contributing factor in the incidence of spondylolysis, with the number of males outnumbering females from roughly 2:1–3:1.[21] In an observational study of 4790 intercollegiate athletes over a 10-year period, Keene et al[27] found that males were found to have higher rates of acute back injuries and thoracolumbar injuries compared with female athletes. There are relatively few studies analyzing the incidence of spondylolysis in American football athletes. In the study by Keene et al,[27] the authors found significantly higher rates of overall back injuries among football players (17%) and gymnasts (11%) compared with other sports. Of these, 21% of back pain in gymnasts and 3% of back pain in football players were attributed to spondylolysis.[27] In a prospective study analyzing 506 college football players at the University of Washington, Semon and Sprengler[28] found that 135 (26.6%) of players experienced back pain at some point during their careers, but only 12 of these players were diagnosed with spondylolysis (2.4% of all players, 20.6% of players with imaging). There was no difference in missed practices or games for these players compared with players without spondylolysis. The authors concluded that spondylolysis only minimally impacted the athlete's ability to play. In another prospective study involving college football players from Indiana University, McCarroll et al[29] found that up to 15.2% of players had evidence of pars defect on plain radiographs, with the highest proportion among linemen, followed by wide receivers, and running backs (Table 1). While interior linemen were generally thought to be at higher risk of spondylolysis, this study suggests that other skilled positions were also significantly affected.[20] Similar to Semon and Sprengler, the authors found the presence of spondylolysis did not negatively affect their careers. They suggested that other factors such as weightlifting, or training techniques also contribute to stress reactions in the pars, and that particular attention should be given to proper techniques of blocking, tackling, weight training, and overall conditioning.[29] In one of the largest prospective studies on American football players, Iwamoto et al[34] analyzed preparticipation radiographs of 171 high school and 742 college football incoming freshmen and found 11.1% and 10.4% prevalence, respectively, of abnormal radiographs indicative of spondylolysis. The authors noted a significantly higher incidence of low back pain in these athletes compared with those without a preexisting spondylolysis, but did not stratify based on position. In contrast, Jones et al[31] compared 104 college football players to 83 age-matched controls and found no significant difference in the prevalence of spondylolysis or back pain.

Data examining professional football players in the National Football League (NFL) is sparse. Brophy et al[32] analyzed college athletes invited to the NFL Combine, where notable players likely to be drafted are invited to showcase their physical skills, and found that a preexisting diagnosis of spondylolysis significantly affected the likelihood of continuing to play in the NFL at the running back position ($P = 0.01$). The authors also noted a trend towards significance at the wide receiver position ($P = 0.06$) with continuing to play in the NFL.[32] Similarly, Schroeder et al[33] retrospectively identified 135 NFL athletes with spondylolysis and with or without an associated slip and noted an overall decrease in career longevity in these athletes. Those with a preexisting diagnosis at the NFL scouting combine also had a significantly lower rate of being drafted than those without. Of note, however, there are many cases at the NFL combine where a player is noted to have a spondylolysis and is totally asymptomatic. These are often incidentally discovered in players with no history of low back pain.

Rugby is a similar collision sport where athletes experience significant axial loading and rotational forces in scrums and tackles that predispose athletes to lumbar stress fractures. As such, certain professional rugby societies have imposed spine screening guidelines for young athletes, potentially restricting the participation of players with spinal abnormalities.[35] Iwamoto et al[30] reported a prevalence of 15.6% of spondylosis in high school rugby players, roughly equivalent to rates reported above for American football.

Stress fractures of the pedicles are much less common than spondylolysis and thus very few studies are present in the literature on this topic. Several reports discuss pedicle fractures in young athletes, ranging from ballet, baseball, basketball, cricket, lacrosse, soccer, and volleyball (Table 2).[14,15,36–41] While broad epidemiological patterns are difficult to describe with limited reports, some authors have speculated pedicle stress fractures are closely related to spondylolysis and may occur due to slight variations in directed force through the spinal posterior elements.[37]

TABLE 1. Prevalence of Spondylolysis and Distribution by Position in American Football

References	Prevalence	Linemen	Wide Receiver	Running Back	Linebacker	Quarterback	Defensive Back
Ferguson et al[20]	College: 6/12 (50%)	6	—	—	—	—	—
Semon and Sprengler[28]	College: 12/58 (20.6%)						
McCarroll et al[29]	College: 22/145 (15.2%)	8	5	4	3	1	1
Iwamoto et al[30]	High school: 11.1% College: 10.4%						
Jones et al[31]	College: 5/104 (4.8%)						
Keene et al[27]	College: 4/133 (3.0%)						
Brophy et al[32]	Professional: 25/1405 (1.78%)	—	14	11	—	—	—
Schroeder et al[33]	Professional: 135/2965 (4.6%)						

Copyright © 2020 Wolters Kluwer Health, Inc. All rights reserved.

Copyright © 2020 Wolters Kluwer Health, Inc. Unauthorized reproduction of this article is prohibited.

TABLE 2. Reports of Pedicle Fractures or Acute Stress Reactions in Athletes

References	Sport	Age/Sex	Findings
Amari et al[36]	Ballet	14/male	Bilateral pedicle fracture at L4 confirmed by CT, not readily evident on x-rays
Abel[37]	Ballet	17/female	Bilateral united pedicle fractures at L4 confirmed by CT
Ireland and Micheli[38]	Ballet	18/female	Bilateral pedicle fracture at L2 confirmed by CT, not appreciated on initial radiographs
Guillodo et al[14]	Gymnast	13/female	Left L5 spondylolysis, followed by right L5 pedicle fracture
Kessous et al[39]	Baseball/ football	16/male	Left L5 spondylolysis, Right L5 pedicle sclerosis and fracture confirmed with CT
Parvataneni et al[40]	Ballet	19/female	Bilateral stress fracture of pedicle at L5, confirmed by CT
Sairyo et al[41] (all patients with contralateral pars defect)	Baseball	17/male	Pedicle fracture
	Baseball	17/male	Pedicle fracture
	Basketball	16/male	Pedicle sclerosis
	Soccer	11/male	Pedicle sclerosis
	Baseball	15/male	Pedicle sclerosis
	Volleyball	20/female	Pedicle sclerosis
Weatherley et al[15]	Cricket	26/male	Right L4 pedicle fracture, seen as sclerosis on plain radiographs, confirmed with bone scan and CT. Contralateral pars defect noticed on bone scan

CT indicates computed tomography.

In fact, in an analysis of 13 patients with unilateral spondylolysis, Sairyo et al[41] showed that 2 patients had contralateral pedicle fractures and 4 other patients showed evidence of stress reaction such as increased sclerosis in the pedicles (46.2%). One baseball player developed successive stress fractures, starting with unilateral spondylolysis then progressing to a contralateral pedicle stress fracture and finally contralateral spondylolysis.[42] The low incidence of these injuries make it difficult to study and develop treatment guidelines. However, biomechanical studies including finite element models may help clarify risk factors for developing pedicle stress fractures. Sairyo et al[41] showed that in a finite element model, having a unilateral spondylolysis significantly increased forces in the contralateral pedicle and pars during lumbar motion in 6 directions (flexion, extension, lateral bending, and axial rotation). In particular, contralateral rotation increased stress concentration at the contralateral pedicle and pars up to 12.6-fold.[41] These findings suggest that surgeons should be aware of contralateral changes in the pedicle and pars when spondylolysis is diagnosed in athletes.

CLINICAL PRESENTATION

Patients with lumbar stress fractures typically present with an insidious onset of back pain. The location of the pain is characteristically localized to the lower back but may radiate into the buttocks or the posterior aspect of the thighs. Aggravating factors include continuing activities, especially those that involve lumbar extension. Pain is typically relieved with rest, cessation of activity, and anti-inflammatories. The severity, extent, and duration of pain may vary depending on several factors including the type of sport, activity level, as well as age. Symptoms may gradually increase over a prolonged period of time ranging from weeks to months. Patients do not typically complain of any neurological abnormalities such as radicular pain or weakness. Any deficits in sport-specific activities such as running or throwing may be limitations secondary to pain. Athletes may also report stiffness in the surrounding hip and thigh areas and difficulties bending over.

Physical examination typically reveals no visual abnormality of the lumbar spine. There may be localized tenderness to the low back and associated muscle spasm. If significant guarding is present, a compensatory lean or list may be seen.[43] In addition, an antalgic gait may occur if the athlete is acutely in pain. Lumbar flexion and extension is often limited due to pain. Jackson et al[44] was the first to describe the one-legged hyperextension test (Stork test), where the patient is asked to stand on one leg and extend their lumbar spine. Recreation of pain on the ipsilateral side signifies the presence of spondylolysis. While this test has historically been considered pathognomonic of spondylolysis, no validation studies have been conducted. Masci et al[45] found that it was neither sensitive nor specific for identifying patients with active spondylolysis. Associated findings may include decreased lumbar lordosis as well as hamstring tightness. A careful neurological examination often will reveal intact sensation, motor strength, and reflexes.

RADIOLOGIC EVALUATION

Proper imaging is central to the accurate diagnosis of stress fractures to the lumbar spine. Imaging can help guide therapy and assess the stage of injury, allowing the physician to determine prognosis and eventual return to play. Diagnostic modalities include plain radiographs, computed tomography (CT), radionuclide scintigraphy [eg, bone scan, single-photon emission computed tomography (SPECT), and magnetic resonance imaging (MRI). The most common initial modality employed is plain lumbar radiographs, including anteroposterior, lateral, and oblique views. The use of dynamic flexion and extension views can help identify the presence of instability. While plain radiographs have low sensitivity to for detecting early stages of stress reactions, they are helpful in ruling out other obvious bony pathology such as tumors. Historically, the lateral oblique or "Scottie dog" view was regarded as useful for visualizing pars defects and is able to identify up to 96% of defects when used in combination with other views (Fig. 1).[46]

Copyright © 2020 Wolters Kluwer Health, Inc. All rights reserved.

Copyright © 2020 Wolters Kluwer Health, Inc. Unauthorized reproduction of this article is prohibited.

FIGURE 1. Lateral oblique view (Scottie dog) of the lumbar spine demonstrating disruption of the pars at the L3 vertebra as demonstrated by the white arrow.

CT is currently considered the gold standard for identifying spondylolysis.[46] It has replaced the lateral oblique view as a more sensitive method of identifying a pars defect.[5] Because of its superior bony resolution, multiplanar imaging capability, and utilization of thin-cut slices, borderline cases that are not readily apparent on plain radiographs may be readily visualized with this modality. When viewing the pars region, a reverse gantry angle is often used to visualize the pars defect in plane. In addition, CTs conducted at multiple timepoints can reliably detect the progression of bony healing, although this is rarely recommended due to excessive radiation exposure and is not typically used to determine return to play. Figure 2 depicts axial and sagittal slices of chronic pars defects visualized at L2 and L3 in 1 patient. The superior resolution provided by CT make it evident that the bony changes have been present for a prolonged period indicating that these are chronic changes. Figure 3 shows axial CT slices of a lumbar vertebrae with increased bony sclerosis and cortical remodeling in the left pedicle that is typical of a stress reaction (Figs. 3A–D).

Bone scintigraphy is a separate modality that uses radionuclear tracers to identify metabolically active bone, thus helping to diagnose the chronicity of spondylolysis or other reactive bone. Bone scans and SPECT have been found to be more sensitive than plain radiographs in detecting pars defects.[47] SPECT is especially useful for identifying evidence of stress reactions before any radiographic changes are evident.[48] In addition, the appearance and quality of tracer uptake can signal whether the reactive lesion is active or inactive, suggesting chronicity.[49] An active bone defect is associated with healing, whereas inactivity likely signals a healed defect or fibrous nonunion. Overall, this modality is less specific since it identifies any metabolically active bone, not just stress reactions. Other causes such as tumors or infections can show similar uptake, thus necessitating additional imaging to increase specificity. SPECT can be combined with CT to anatomically localize active lesions. This can be performed using 2 separate imaging sequences for SPECT and CT, respectively and merged afterward. Currently, there are scanners are available that perform both imaging modalities simultaneously to generate a SPECT-CT image.

MRI's advantages include the lack of ionizing radiation as well as the ability to assess other pathology, such as compression on neural elements and discogenic injuries. It is useful when CT scans are normal for any bony changes. Increased edema on T2-weighted sequences can be indicative of prelysis stress lesions, especially ones that are amenable to bony healing.[50] T1-weighted sequences can be used to for discontinuities in the cortex and changes in marrow edema. In addition, signal changes can be indicative of the chronicity of the lesion. While it has a poor positive predictive value (14%) and only moderate sensitivity (57%), it has a high negative predictive value (97%).[5] Compared with CT scans, it has a poorer resolution in the small region of the pars interarticularis but an adequate resolution for the pedicle region. In a prospective study directly comparing MRI with CT and bone scintigraphy among young active subjects with acute onset low back pain, Masci and colleagues found that MRI was equivalent to CT in identifying active spondylolysis, but inferior compared with SPECT. This is in contrast to the findings by Campbell et al,[51] who found that MRI was equivalent to CT and the combination of SPECT-CT. Several variables may explain the variation in MRI use as a diagnostic modality, including signal quality, imaging sequences used, as well as operator error. Overall, MRI is the imaging modality of choice as it has no radiation and will detect lumbar disk issues as well. MRI's sensitivity approaches up to 90% in cases of spondylolysis or stress responses. If the MRI is negative, no further imaging is generally warranted.

Centers have developed their own imaging protocols utilizing these different modalities. The protocol at Children's Hospital Boston utilizes plain x-ray imaging, followed by SPECT scans in patients presenting with pain on hyperextension.[52] If SPECT scans are positive for diffuse uptakes, these are graded as stress reactions, whereas focal uptake may be representative of a fracture requiring a CT scan. McCleary et al[5] proposed plain radiographs, followed by SPECT scan or MRIs if radiographs are negative. Patients with positive uptake on SPECT scans or positive findings on MRI undergo CT scans at 12 weeks to evaluate fracture anatomy and healing, and also to help evaluate prognosis. In a prospective study of 200

Copyright © 2020 Wolters Kluwer Health, Inc. All rights reserved.

Copyright © 2020 Wolters Kluwer Health, Inc. Unauthorized reproduction of this article is prohibited.

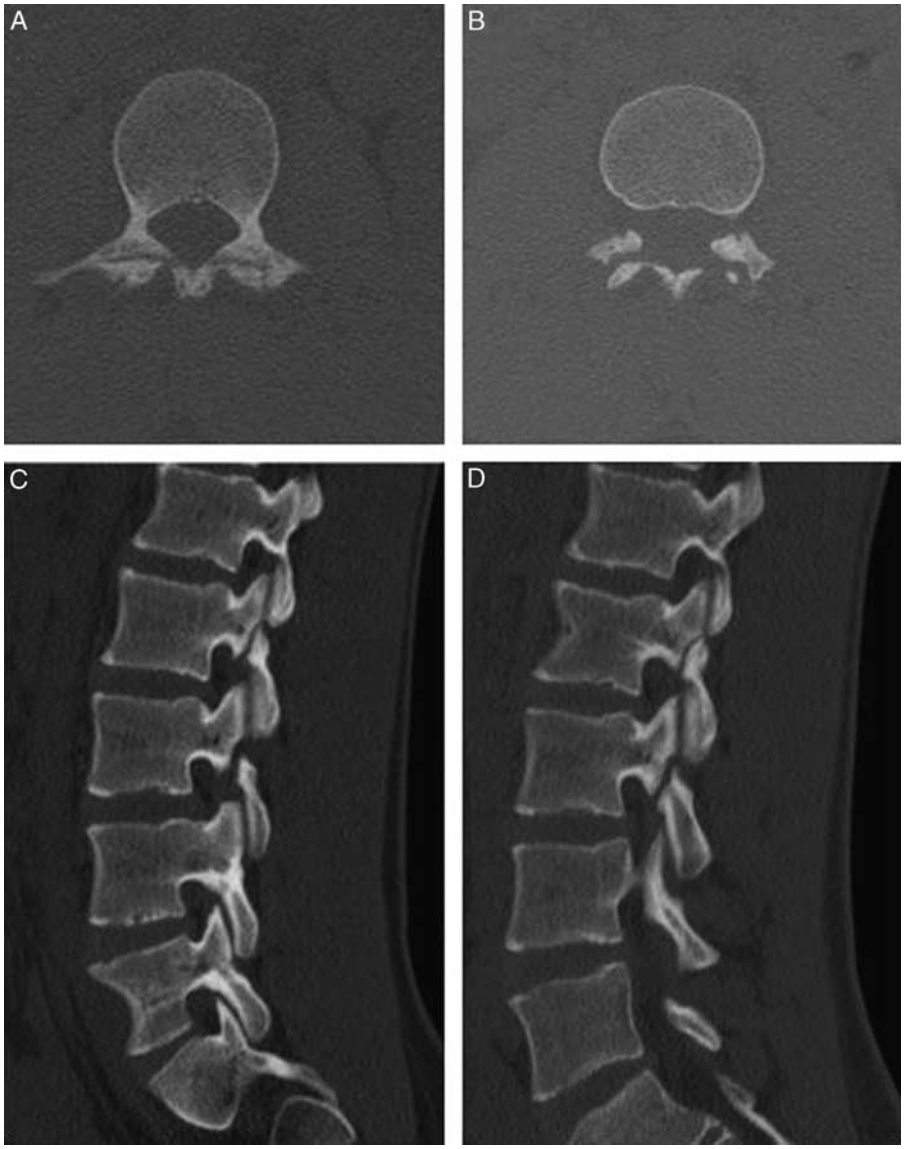

FIGURE 2. A and B, Axial slices of pars defects at L2 and L3. C and D, Depict left and right parasagittal slices on computed tomography demonstrating pars defects at L2 and L3.

adolescent athletes presenting with low back pain, plain radiographs, and MRI were used as initial imaging modalities and CT was subsequently performed if intensity changes were observed in the pedicle on MRI.[53] Overall, 97 athletes showed evidence of active spondylolysis on MRI that were missed with plain radiographs, with CT showing that the majority of patients were in the nonlysis stage or very early stage of spondylolysis.[53] While these are just a few examples of imaging protocols, practices vary widely, especially for centers caring for professional athletes.

In addition, diagnostic injections have been described as an additional modality of identifying active spondylolysis as the etiology of back pain in patients with multiple pathologies or a mixed clinical picture.[54,55] Wu et al[54] described a positive response in pain reduction in 93 of 275 patients with back pain symptoms and a negative bone scan that underwent a pars injection with a local anesthetic. Kershen et al[55] found that 92% of fluoroscopically guided pars injection were successful in reducing back pain. However, when considering chronic pars fractures, Wald et al[56] found that CT-guided pars injections may only implicate pars defects as the primary pain generator in a smaller subgroup of patients.

TREATMENT

Historically, treatment protocols have varied based on physician preferences and are tailored towards individual situations. The initial treatment is generally conservative with the initiation of a period of rest to allow healing of the reactive bone or fracture. Similar to

Copyright © 2020 Wolters Kluwer Health, Inc. All rights reserved.

Copyright © 2020 Wolters Kluwer Health, Inc. Unauthorized reproduction of this article is prohibited.

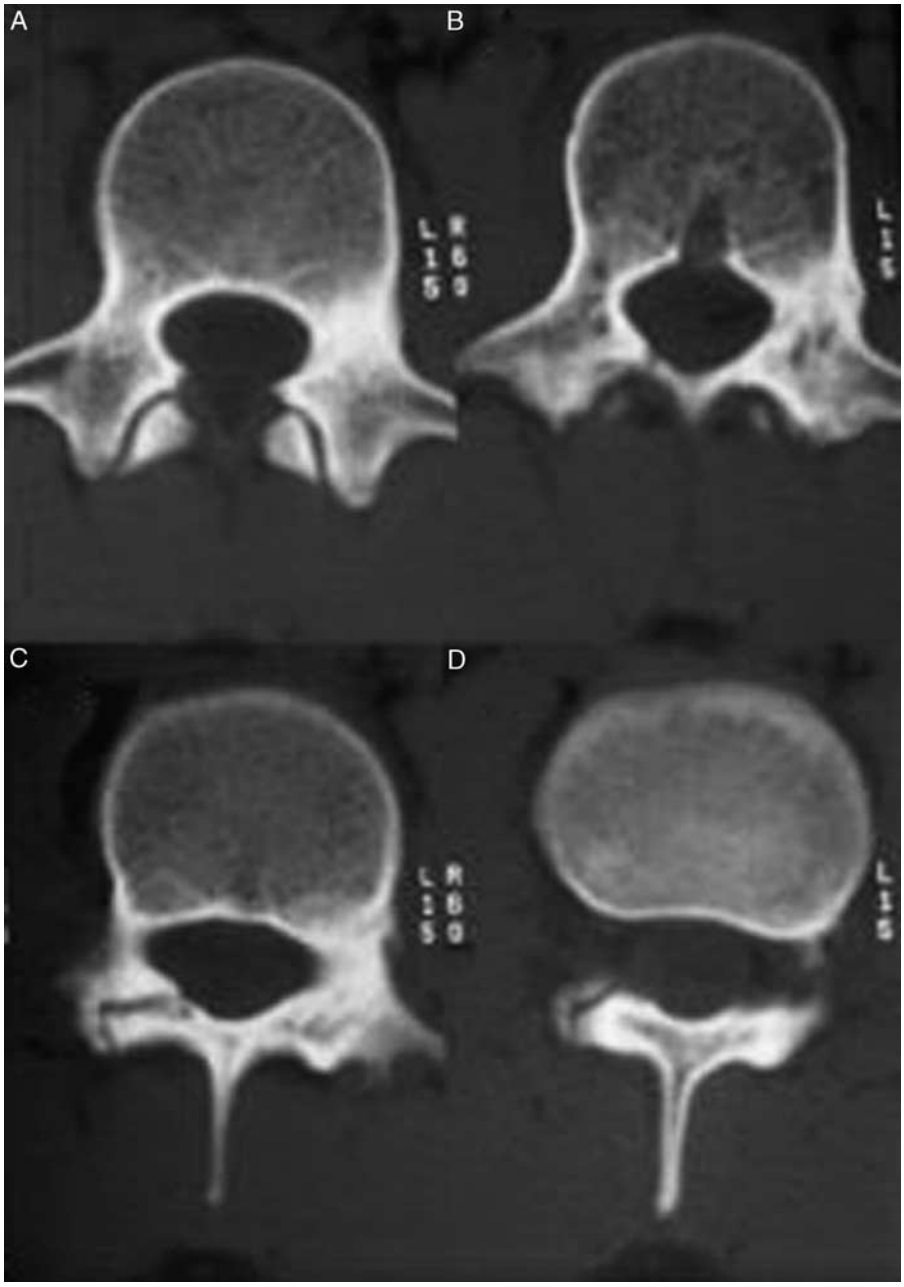

FIGURE 3. A–D, Consecutive axial computed tomography slices of a patient with a stress reaction in the left pedicle as evidenced by the increased bony sclerosis and cortical remodeling along with a unilateral right-sided spondylolysis.

bone stress lesions in the appendicular skeleton (eg, tibia, femur), the time frame for healing can be several months. Activity modification alone may be the most important reason for improvement. Bracing has been used as an adjunct to limit lumbar extension and theoretically reduce stress on the pars region. However, the duration of bracing and the weaning protocols can vary widely between physicians. Studies suggest that compliance with the brace may be more important than the actual type of brace used and the brace is typically discontinued once the patient is asymptomatic.[49] Therefore bracing is typically viewed as a supportive measure until the athlete is able to return to sport pain-free. To date, no studies have assessed whether bracing with the addition of a thigh extension is beneficial. However, historically these types of braces were associated with significant patient noncompliance. Other controversial treatment modalities include the use of electrical bone stimulation to increase rates of bone healing.

Popular treatment protocols for pars stress fractures have involved restricting patients from the activity and the initial use of an antilordotic Boston brace that is worn full-time for 4–6 weeks.[52,57] This period of time usually allows

Copyright © 2020 Wolters Kluwer Health, Inc. All rights reserved.

Copyright © 2020 Wolters Kluwer Health, Inc. Unauthorized reproduction of this article is prohibited.

for a period of rest to allow the symptoms to subside. During this time, the lumbar extension is avoided and the patient may start physical therapy targeting flexion exercises and improving core strength and pelvic flexibility. After 4–6 weeks, if pain with extension is resolved, the athlete can return to sport-specific drills and impact conditioning. The length of brace wear is controversial and often varies depending on the treatment center. In a meta-analysis, Overley et al[58] showed that elite-level athletes with a mean age of 18.1 years undergoing nonoperative treatment had a return to play rate of 93% at an average of 5.9 months after starting treatment.

Conservative treatment of pedicle stress fractures also vary but focus on rest and physical therapy for core stabilization. In highly active athletes, some reports have suggested restrictions from sports, full-time thoracolumbosacral bracing, and analgesics from 6 weeks to 3 months, followed by repeat imaging to demonstrate evidence of healing with the formation of bony callus.[40–42,50] Sairyo et al[42] demonstrated full healing and bony union at the 4-month point in an active 17-year-old baseball player who was allowed to return to play at that time. At the 6-month point, the player was asymptomatic and returned to competitive play. In another study, Sairyo et al[41] showed complete bony healing on CT at the 6-month point in a baseball player with a pedicle stress fracture. Kessous et al[39] reported a pain-free examination and full healing of a pedicle fracture at the 4-month point in a varsity football athlete. At 5 months, the patient returned to full-contact sports including competitive football and remained asymptomatic through long-term follow-up. Some athletes may not heal their pedicle stress fractures and become asymptomatic with a stable nonunion. If they are pain-free and no instability exists, they can be cleared to play.

Operative treatment is generally the last resort for the management of stress fractures in the lumbar spine. Patients who have failed nonoperative treatment for a significant period of time (12 mo or more) and have developed a symptomatic fibrous nonunion of the pars may be candidates. The presence of bilateral spondylolysis can lead to instability and subsequent neurological symptoms. Early historical treatment of a symptomatic L5 spondylolysis was debridement of the fibrous nonunion in the pars region and performing an in situ L5–S1 fusion with autologous iliac crest bone graft.[49] Today, the vast majority of surgeons will perform an instrumented fusion with or without an interbody spacer if a fusion is selected. Decompression by removing the L5 lamina is called a Gill procedure and involves resection of the posterior elements through the pars defects and a foraminal decompression.

Techniques to avoid fusion have been developed and involve direct repair of the pars defect (Fig. 4). These include removal of fibrous nonunion at the pars and interfragmentary fixation with a compression screw across the pars defect (Fig. 4A, Buck direct repair technique), tension band wiring around the transverse process and lamina (Fig. 4B, Scott wiring technique), pedicle screw-up going hook fixation below the involved lamina (Fig. 4C), and bilateral pedicle screw fixation with a rod tension band below the affected lamina (Fig. 4D).[59–62] These techniques are all motion-sparing and rely on the fact that no significant instability, symptomatic disk herniation, or disk degeneration exist at the motion segment. Overley et al[58]

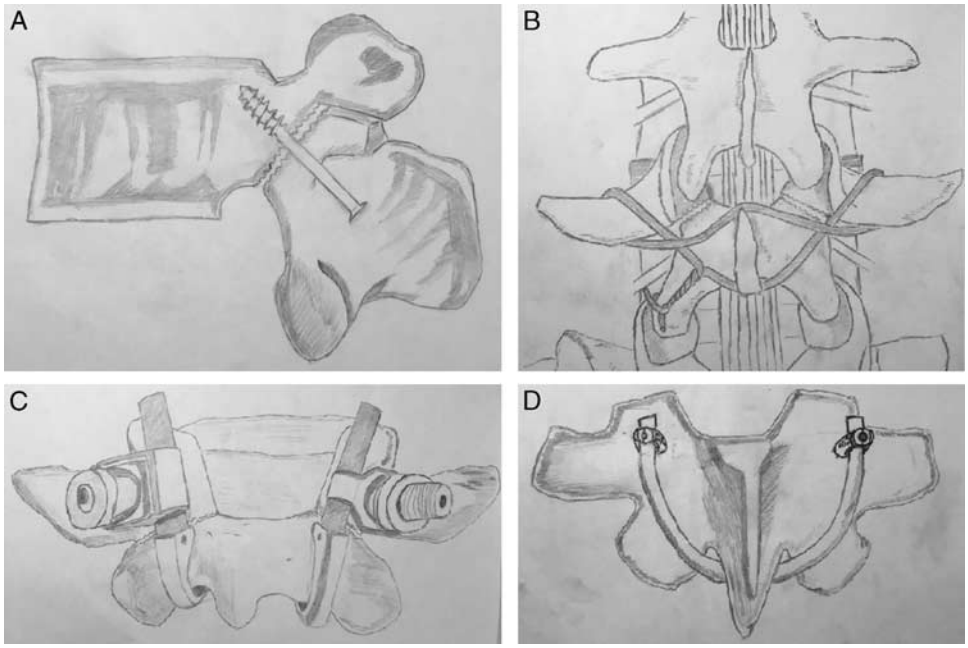

FIGURE 4. A, Buck compression screw. B, Scott wiring technique. C, Pedicle screw-infralaminar hook construct. D, Pedicle screw-tension band system.

Copyright © 2020 Wolters Kluwer Health, Inc. All rights reserved.

Copyright © 2020 Wolters Kluwer Health, Inc. Unauthorized reproduction of this article is prohibited.

showed that elite-level patients undergoing operative treatment with variations of pars compression screws or tension band wiring performed well and had a return to play rate of 90.3% at an average of 6.5 months after surgery.

The fixation of pedicle fractures has been less well described but may consist of placing a unilateral pedicle screw in compression across the fracture site.[63] This method can avoid fusion in young athletes and may be done in a minimally invasive fashion.

TREATMENT GUIDELINES AND RETURN TO PLAY

A high index of suspicion is the key to the diagnosis of stress fractures in athletes. Performing a complete history and physical examination can be challenging when accommodating for elite athletes. The physician must strive to maintain the same comprehensive medical diagnosis and treatment for all patients. As treatment practices vary across the country, this section summarizes diagnostic and rehabilitation protocols and return to play guidelines from 4 physicians that all actively treat professional NFL athletes.

Los Angeles—Dr Robert Watkins III and Dr Robert Watkins IV

In any high-level athlete with 3–6 weeks of back pain, a bone scan with lumbar SPECT is performed. If the SPECT scan is positive, a CT scan is done to identify the lesion (Fig. 5). Software that merges the SPECT scan onto the CT scan is very effective to show the patient, parents, and other concerned parties exactly the pathology. The SPECT-CT combination also estimates the age and healing potential of the lesion. If the SPECT scan is negative, an MRI is done to identify discogenic injuries. Many patients initially have an MRI performed because it is faster, more readily available in the community, less costly, and without radiation exposure. An MRI is adequate for diagnosis and treatment in many patients. However, if a patient is not responding to treatment and/or requires detailed diagnosis and prognosis, then a SPECT-CT is performed.

Treatment is the same whether the fracture is in the pars interarticularis or pedicle. The pedicle has a better blood supply and may have a higher chance of bony union. However, a displaced fracture in the pedicle may cause foraminal stenosis and radiculopathy. We correct any vitamin D deficiencies in all patients with stress fractures. The use of Forteo is reasonable in professional athletes. Initially, we treat with anti-inflammatories to decrease the pain. Occasionally, we perform a pars block and transforaminal epidural to decrease severe symptoms.

Stopping the activity that provokes pain is essential to recovery from stress fractures. A brace may make a teenager more compliant with not performing athletic activities that provoke pain. The SPECT-CT scan that clearly illustrates the pathology can also make an athlete more compliant with the treatment program. We do not brace because we believe that an effective brace to prevent stress across the lumbosacral junction requires immobilization of the pelvis and hip joints which is not realistic in modern society. We have found that treatment depends on stopping the provocative activity and building muscle strength to protect the injured segment.

FIGURE 5. Single-photon emission computed tomography-computed tomography scan using software to merge both imaging sequences and localize active lesions. full color online

Our back rehabilitation program (available in the Back Doctor App, Fig. 6) establishes a pain-free neutral spine position. The rehabilitation begins immediately because the exercises do not stress the injured spine. There are 7 categories of back exercises, each 1 with 5 levels of increasing difficulty and endurance. The program trains the muscles to maintain a neutral pain-free position while adding balance and coordination. The athlete progresses through the levels as long as they are able to maintain the proper neutral position without pain. On the basis of the average level obtained, the athlete is allowed to return to specific activities. Level 2 allows elliptical, biking, swimming, and rotator cuff exercises. Level 3 allows running, weightlifting, throwing, hitting, shooting, skating, rotation, and sport-specific exercises. Level 4 allows squatting, deadlifting, and practicing with the

Copyright © 2020 Wolters Kluwer Health, Inc. All rights reserved.

Copyright © 2020 Wolters Kluwer Health, Inc. Unauthorized reproduction of this article is prohibited.

	Level 1	Level 2	Level 3	Level 4	Level 5
Dead Bug	Supported Arms, Marching Legs, 2 Min. or Supported Legs, Extended Arms, 2 Min.	Unsupported, Alternate Opposite Arms & Legs, 3 Min.	Unsupported, Alternate Opposite Arms & Legs, 7 Min.	Unsupported, Alternate Opposite Arms & Legs, 10 Min. May Add Weights.	Unsupported, Alternate Opposite Arms & Legs, 15 Min. May Add Weights.
Partial Sit-Up	Forward, Hands on Chest, 10 Reps.	Forward, Hands on Chest, 3 Sets x 10 Reps.	Hands Behind Head; Forward, Right, Left: 3 Sets x 10 Reps.	Weight on Chest: Forward, Right, Left: 3 Sets x 20 Reps.	Weights Overhead: Forward, Right, Left: 3 Sets x 30 Reps.
Bridging	Double Leg Supported, 2 Sets x 10 Reps.	Double Leg Supported 2 Sets x 20 Reps. May Add Weights to Hips	Single Leg Supported, Alternate Opposite Leg Extended, 3 Sets x 20 Reps, Each Side.	On Ball, Single Leg Extended, 4 Sets x 20 Reps, Each Side.	On Ball, Single Leg Extended, 5 Sets x 20 Reps, Each Side. With Ankle Weights.
Prone	Alternating Arm or Leg Lifts, 1 Set x 10 Reps, Hold 2 Sec.	Alternating Opposite Arm and Leg Lifts, 2 Sets x 10 Reps, Hold 5 Sec. Each Side.	On Ball: Flys, Swim, Supermans: 2 Sets x 20 Reps, Hold 5 Sec.	On Ball: Flys, Swim, Supermans w/ Weights, 2 Sets x 20 Reps. Walkout/pushups 3 Sets x 5 Reps.	On Ball: Flys, Swim, Supermans w/ Weights, 4 Sets x 20 Reps. Walkout/pushups 4 Sets x 10 Reps.
Quadruped	Alternate Arm or Leg, 1 Set x 10 Reps, Hold 2 Sec. Each Side.	Alternating Opposite Arm and Leg, 2 Sets x 10 Reps, Hold 5 Sec. Each Side.	Alternating Opposite Arm and Leg, 2 Sets x 20 Reps, Hold 5 Sec, Each Side.	Alternating Opposite Arm and Leg, 3 Sets x 20 Reps, Hold 5 Sec., w/ Weights.	Alternating Opposite Arm and Leg, 3 Sets x 20 Reps, Hold 15 Sec., w/ Weights.
Wall Slide	45 Degress, 10 Reps, Hold 5 Sec.	90 Degrees, 10 Reps x 20 Sec.	90 Degrees, 10 Reps x 30 Sec. Lunges 1 Min.	90 Degrees, Weights at Side, 10 Reps x 30 Sec. Lunges w/ Weights at Side 3 Min.	90 Degrees, Weights with Arms Extended, 10 Reps x 30 Sec. Lunges w/ Weights in Front 5 Min.

FIGURE 6. Watkins back rehabilitation program. Shown here are categories of back exercises, each with 5 levels of progressive difficulty and endurance. full color online

team. Level 5 allows professional athletes to return to sport. Return to play depends on:

(1) Achieving the proper level of the stabilization program:
   - Level 3 for recreational athletes.
   - Level 4 for college athletes.
   - Level 5 for professional athletes.
(2) Obtaining good aerobic conditioning.
(3) Performing the sport-specific exercises.
(4) Returning gradually to the sport (ie, minutes progression).
(5) Continuing the stabilization exercise once the athlete returns to sport.

In our practice, surgical treatment for stress fractures is very rare. If an athlete has failed a proper rehabilitation program for 6–12 months, depending on the unique circumstances of the case, surgical repair is an option. We have performed several direct pars repairs under image-guidance with success. If a fusion is indicated for spondylolisthesis, we typically perform an anterior interbody fusion followed by posterior pedicle screw fixation.

Dallas—Dr Andrew Dossett

For an acute pars stress reaction or fracture, our recommendations are that they rest from the activity for a period of 3 months. They are not to take any nonsteroidal anti-inflammatories as this has some evidence to delay bone healing. If the stress reaction and/or fracture is at L3 or above we brace with a lumbosacral orthotic. If the stress reaction is at L4 or L5, no bracing is necessary as the literature suggests that a thigh cuff is necessary to properly immobilize.

At the 6-week follow-up, if the Jackson maneuver (Stork test) is negative and the examination has normalized, the patient is started on a nonimpact aerobic conditioning program as well as an isometric core stability program specifically avoiding extension and flexion. At 3 months, if the examination remains normal, the patient is started on a dynamic core stability program and reintegrated into their respective sport. We do not reimage at 3 months if the patient is a teenager, since healing may not go on to occur in a young patient at this timepoint. In older professional athletes, both CT and MRI are obtained to assess healing on CT and edema on MRI. Anecdotally, only about 50% of stress fractures at L4 and L5 heal.

Treatment of pedicle fractures can be slightly more difficult and healing time is likely prolonged by an additional 3 months. The same protocol mentioned above is used, however, the time is altered with conditioning and strengthening started at 3 and 6 months instead of 6 and 12 weeks.

In 25 years of treating athletes with pedicle stress fractures and pars stress fractures, no patients have required surgery for treatment, as rest and appropriate rehabilitation seem to work. In this practice, the most commonly encountered sport for pedicle fractures is baseball followed by Olympic gymnasts. In the late 1990s, the 40-man roster of the Texas Rangers was evaluated

Copyright © 2020 Wolters Kluwer Health, Inc. All rights reserved.

Copyright © 2020 Wolters Kluwer Health, Inc. Unauthorized reproduction of this article is prohibited.

radiographically during 2 consecutive spring training periods. The incidence of chronic spondylolysis within this group of athletes was just over 20%, indicating that it may be endemic in baseball players.

New York—Dr Andrew Hecht

When a young athlete presents with low back pain, we prefer to use MRI (after initial radiographs) as the first choice for imaging. MRI is useful as it will detect most acute stress responses, chronic pars defects, and lumbar disk herniations. Sometimes a CT will miss a stress response as bony edema is not something detectable on a CT scan. Even though MRI will miss ~8% of spondylolysis cases it will also rule out other common causes of the low back in an athlete such as disk herniation, sacral stress fractures, and inter-spinous ligament injuries (which are often mistaken for spondylolysis). If the MRI is negative, a SPECT/CT scan will then be obtained. Once the diagnosis is made of a pars defect or pedicle fracture, our conservative treatment protocol consists of a Boston overlap brace for 4 weeks and with a subsequent reexamination of the patient. This allows modification and limitation of the athlete's activity level and stresses, particularly for young athletes, without altering the natural history of the healing of either a spondylolysis or pedicle fracture.

If the athlete is still symptomatic after 4 weeks of conservative treatment, with either complaint of pain or pain on lumbar extension during a physical examination, we will continue the brace for another 4 weeks. If they are asymptomatic, we will then start a trunk isometric physical therapy program designed by Drs Watkins described elsewhere in this article. Even if symptomatic at 8 weeks, we will then start the physical therapy program and remove the brace.

If the athlete is asymptomatic after 4 weeks (the most common scenario), the above-mentioned physical therapy protocol is initiated. Once the athlete gets to at least level 3 of the Watkins protocol, we will then begin sport-specific activities with a gradual return to play between 8 and 12 weeks if asymptomatic.

At this center, we have rarely ever had to operatively treat a stress fracture of the pars or pedicle. If the athlete has recalcitrant symptoms from a pars defect, the surgical technique will include direct repair with either pedicle screw/hook construct or cortical screw construct with a very small amount of iliac crest autograft. Most pars defects are sclerotic defects and need bone grafting to heal despite the small size. Pedicle fractures can usually be repaired with lag screw fixation (usually bilaterally). The critical point is that the need to repair either of these injuries is exceedingly rare.

Philadelphia—Dr Alexander Vaccaro

For the diagnosis of acute stress lesions in a symptomatic athlete, we prefer to use MRI as the advanced imaging modality due to its convenience and availability. While CT scans are superior for the definition of bony elements, faint fracture lines may be very difficult to detect in early lesions. Contrarily, edema in the pedicle present on T2-weighted sequences are highly sensitive for acute stress reactions. Similar to the use of MRI in detecting stress fractures elsewhere, changes in T2 signal indicate the presence of bone marrow edema and suggest increased biomechanical stresses. This allows the detection of abnormal anatomy as well as increased metabolic activity without the need for a SPECT-CT scan. In addition, MRI can simultaneously identify any abnormalities to surrounding tissues such as the nerves or disk space. Along with a thorough examination of the athlete, this helps in the diagnosis of acute stress reactions. These benefits are particularly applicable to adolescent athletes, who may be spared additional radiation with a CT and nuclear medicine scan. In progressive or late lesions, however, a CT can more clearly delineate the stage of healing and demonstrate bony union.

Nonoperative treatment for both pars and pedicle stress fractures often spans a treatment period of 3–4 months, including a combination of rest from the sport causing injury, as well as rehabilitation in a pain-free, neutral spine position. The rehabilitation and rest duration may be extended in cases of a pedicle stress fracture, depending on the athlete's symptomatology and examination findings. Initially, bracing is often used for 4–6 weeks in the adolescent athlete, and occasionally in the adult contact athlete depending on the identified lesion on advanced imaging studies. In the adult athlete, braces are not particularly helpful as we have found that patients are noncompliant and it is particularly ineffective for pars lesions at L4 and L5 as concomitant pelvic immobilization is also required for adequate immobility. In some adult cases, we also recommend the use of external electric stimulation and a bone health consult to see if medicinal treatment (ie, Forteo), may be helpful. Forteo (teriparatide) is a 34-amino acid parathyroid hormone analog that acts as an anabolic agent for increasing bone density. Administration of this medication has been trialed in the use of stress fractures with some beneficial response.[64] However, both recommendations have not been universally accepted, as more studies are necessary to understand their benefits.

Focused physical therapy is imperative and includes a combination of muscle strengthening, muscle lengthening, proprioceptive training, and optimization of joint kinematics. Initially, the patient is asked to follow spinal precautions, including avoidance of lumbar extension, lateral flexion, and rotation for 8–12 weeks, as well as any activities that reproduce pain. The lumbosacral brace is removed during therapy, and the rehabilitation program established by Dr Watkins can begin once a patient's severe spasm has subsided. We couple the Watkins' Protocol with bracing and core truncal exercises (hollowing) using a pressure biofeedback unit to promote isolated deep multifidi and transversus abdominus neuromuscular control. Acute rehabilitation also includes a progression of sport-specific and position-specific static and dynamic proprioceptive training, aquatic therapy for cardiovascular endurance, joint mobilization, and soft tissue manipulation. Pulsed thermal

Copyright © 2020 Wolters Kluwer Health, Inc. All rights reserved.

Copyright © 2020 Wolters Kluwer Health, Inc. Unauthorized reproduction of this article is prohibited.

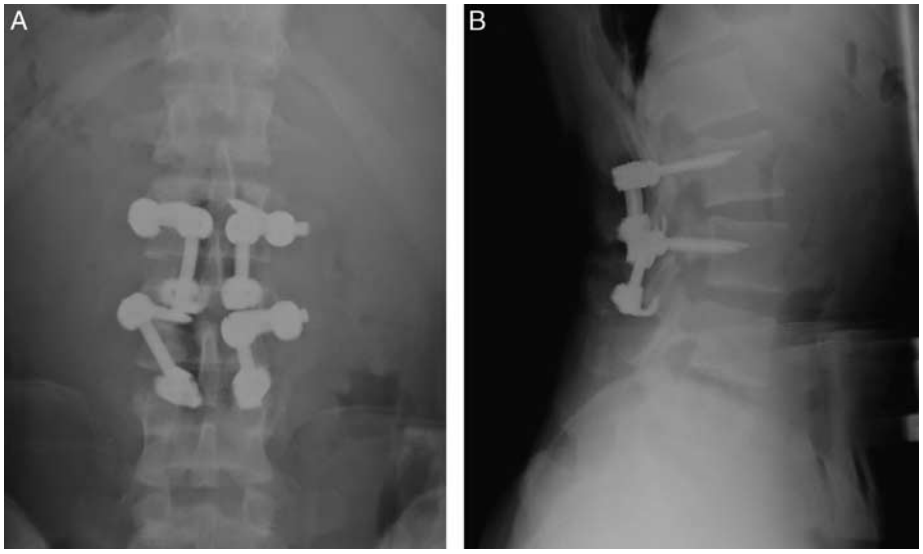

FIGURE 7. Multilevel spondylolysis repaired using a pedicle screw and laminar hook construct as seen in the coronal view (A), and sagittal view (B).

ultrasound may also be used along the fracture site, as some literature supports the use of this modality to promote bone healing.[65]

Spinal precautions are usually uplifted around 2–3 months, and the patient begins a sport-specific and position-specific progression at that time. First, the patient begins a gradual running progression in the sagittal plane only, followed by a progression of multidirectional movements 2–3 weeks later, so that extension and rotation of the lumbar spine are not initiated simultaneously. Both the volume and intensity of training are tracked using a wearable accelerometer and are slowly progressed to the patient's historic workload as long as the patient remains pain-free. If symptoms are still present at 3 months, continued therapy with modifications in the therapy protocol are made until they improve. Rarely is advanced imaging obtained again such as CT due to excessive radiation exposure. However, if the patient is recalcitrant to conservative treatment then a CT may be obtained to assess fracture healing status.

Operative treatment of stress fractures in this practice is rare and heavily case-dependent. In professional athletes, conservative management with rest and focused rehabilitation achieves excellent results in acute stress reactions and thus operative treatment is rarely indicated. In cases of adolescent spondylolysis with recalcitrant symptoms, direct repair with placement of the bone graft and motion-sparing instrumentation may be used. Figure 7 depicts a case of multilevel spondylolysis in an adolescent athlete that was treated using bilateral screw-lamina hook constructs.

CONCLUSIONS

Acute lumbar stress fractures are relatively common phenomena in highly active individuals, however, there is limited literature suggesting treatment guidelines, especially for lumbar pedicle fractures. The literature outlined here combined with specific treatment guidelines suggest that patients overall do well with restriction from sports and focused physical therapy. Surgical techniques exist for the treatment of acute stress reaction, however, this decision must be made on a case-by-case basis.

REFERENCES

1. Daniels JM, Pontius G, El-Amin S, et al. Evaluation of low back pain in athletes. *Sports Health*. 2011;3:336–345.
2. Bono CM. Low-back pain in athletes. *J Bone Joint Surg Am*. 2004; 86:382–396.
3. Rice SG. American Academy of Pediatrics Council on Sports Medicine and Fitness. Medical conditions affecting sports participation. *Pediatrics*. 2008;121:841–848.
4. Wiltse LL, Widell EH, Jackson DW. Fatigue fracture. The basic lesion in isthmic spondylolisthesis. *J Bone Joint Surg A*. 1975;57: 17–22.
5. McCleary MM, Congeni JA. Current concepts in the diagnosis and treatment of spondylolysis in young athletes. *Curr Sports Med Rep*. 2007;6:62–66.
6. Chosa E, Totoribe K, Tajima N. A biomechanical study of lumbar spondylolysis based on a three-dimensional finite element method. *J Orthop Res*. 2004;22:158–163.
7. Dietrich M, Kurowski P. The importance of mechanical factors in the etiology of spondylolysis—a model analysis of loads and stresses in the human lumbar spine. *Spine (Phila Pa 1976)*. 1985;10:532–542.
8. Cyron BM, Hutton WC. The fatigue strength of the lumbar neural arch in spondylolysis. *J Bone Joint Surg Br*. 1978;60-B:234–238.
9. Araki T, Harata S, Nakano K, et al. Reactive sclerosis of the pedicle associated with contralateral spondylolysis. *Spine (Phila Pa 1976)*. 1992;17:1424–1426.
10. Aland C, Rineberg BA, Malberg M, et al. Fracture of the pedicle of the fourth lumbar vertebra associated with contralateral spondylolysis. Report of a case. *J Bone Joint Surg Am*. 1986;68:1454–1455.
11. Garber JE, Wright AM. Unilateral spondylolysis and contralateral pedicle fracture. *Spine (Phila Pa 1976)*. 1986;11:63–66.
12. Gunzburg R, Fraser RD. Stress fracture of the lumbar pedicle. Case reports of "pediculolysis" and review of the literature. *Spine (Phila Pa 1976)*. 1991;16:185–189.
13. Gerrard DF, Doyle TC. Lumbosacral pain in an athlete: an unusual site for stress fracture. *Clin J Sport Med*. 1998;8:59–61.
14. Guillodo Y, Botton E, Saraux A, et al. Contralateral spondylolysis and fracture of the lumbar pedicle in an elite female gymnast: a case report. *Spine (Phila Pa 1976)*. 2000;25:2541–2543.

Copyright © 2020 Wolters Kluwer Health, Inc. All rights reserved.

Copyright © 2020 Wolters Kluwer Health, Inc. Unauthorized reproduction of this article is prohibited.

15. Weatherley CR, Mehdian H, Vanden Berghe L. Low back pain with fracture of the pedicle and contralateral spondylolysis. *J Bone Joint Surg*. 1991;73-B:990–993.
16. Cyron BM, Hutton WC. Variations in the amount and distribution of cortical bone across the partes interarticulares of L5. A predisposing factor in spondylolysis? *Spine (Phila Pa 1976)*. 1979;4:163–167.
17. Frederickson BE, Baker D, McHolick WJ, et al. The natural history of spondylolysis and spondylolisthesis. *J Bone Joint Surg*. 1984;66-A: 699–707.
18. Rosenberg NJ, Bargar WL, Friedman B. The incidence of spondylolysis and spondylolisthesis in nonambulatory patients. *Spine (Phila Pa 1976)*. 1981;6:35–38.
19. Debnath UK, Scammell BE, Freeman BJC, et al. Predictive factors for the outcome of surgical treatment of lumbar spondylolysis in young sporting individuals. *Glob Spine J*. 2018;8:121–128.
20. Ferguson RJ, Mcmaster JH, Stanitski CL. Low back pain in college football linemen. *J Sports Med*. 1974;2:63–69.
21. Standaert CJ, Herring SA. Spondylolysis: a critical review. *Br J Sports Med*. 2000;34:415–422.
22. Micheli LJ, Wood R. Back pain in young athletes. *Arch Pediatr Adolesc Med*. 1995;149:15–18.
23. Amato M, Totty WC, Gilula LA. Spondylolysis of the lumbar spine: demonstration of defects and laminal fragmentation. *Radiology*. 1984;153:627–629.
24. Morita T, Ikata T, Katoh S, et al. Lumbar spondylolysis in children and adolescents. *J Bone Joint Surg Br*. 1995;77-B:620–625.
25. Rossi F, Dragoni S. Lumbar spondylolysis: occurrence in competitive athletes. Updated achievements in a series of 390 cases. *J Sports Med Phys Fitness*. 1990;30:450–452.
26. Soler T, Calderó C. The prevalence of spondylolysis in the spanish elite athlete. *Am J Sports Med*. 2000;28:57–62.
27. Keene J, Albert M, Springer S, et al. Back injuries in college athletes. *J Spinal Disord Tech*. 1989;2:190–195.
28. Semon RL, Sprengler D. Significance of lumbar spondylolysis in college football players. *Spine (Phila Pa 1976)*. 1981;6:172–174.
29. McCarroll JR, Miller JM, Ritter MA. Lumbar spondylolysis and spondylolisthesis in college football players: a prospective study. *Am J Sports Med*. 1986;14:404–406.
30. Iwamoto J, Abe H, Tsukimura Y, et al. Relationship between radiographic abnormalities of lumbar spine and incidence of low back pain in high school rugby players: a prospective study. *Scand J Med Sci Sports*. 2005;15:163–168.
31. Jones DM, Tearse DS, El-Khoury GY, et al. Radiographic abnormalities of the lumbar spine in college football players: a comparative analysis. *Am J Sports Med*. 1999;27:335–338.
32. Brophy RH, Lyman S, Chehab EL, et al. Predictive value of prior injury on career in professional American football is affected by player position. *Am J Sports Med*. 2009;37:768–775.
33. Schroeder GD, Sean Lynch T, Gibbs DB, et al. Pre-existing lumbar spine diagnosis as a predictor of outcomes in National Football League athletes. *Am J Sports Med*. 2015;43:972–978.
34. Iwamoto J, Abe H, Tsukimura Y, et al. Relationship between radiographic abnormalities of lumbar spine and incidence of low back pain in high school and college football players: a prospective study. *Am J Sports Med*. 2004;32:781–786.
35. Castinel BH, Adam P, Prat C. A stress fracture of the lumbar spine in a professional rugby player. *Br J Sports Med*. 2007;41:337–338.
36. Amari R, Sakai T, Katoh S, et al. Fresh stress fractures of lumbar pedicles in an adolescent male ballet dancer: case report and literature review. *Arch Orthop Trauma Surg*. 2009;129:397–401.
37. Abel MS. Skeletal radiology jogger's fracture and other stress fractures of the lumbo-sacral spine. *Skeletal Radiol*. 1985;13:221–227.
38. Ireland M, Micheli L. Bilateral stress fracture of the lumbar pedicles in a ballet dancer: a case report. *J Bone Joint Surg*. 1987;69:140–142.
39. Kessous E, Borsinger T, Rahman A, et al. Contralateral spondylolysis and fracture of the lumbar pedicle in a young athlete. *Spine (Phila Pa 1976)*. 2017;42:E1087–E1091.
40. Parvataneni HK, Nicholas SJ, McCance SE. Bilateral pedicle stress fractures in a female athlete. *Spine (Phila Pa 1976)*. 2004;29: E19–E21.
41. Sairyo K, Katoh S, Sasa T, et al. Athletes with unilateral spondylolysis are at risk of stress fracture at the contralateral pedicle and pars interarticularis: a clinical and biomechanical study. *Am J Sports Med*. 2005;33:583–590.
42. Sairyo K, Katoh S, Sakamaki T, et al. Three successive stress fractures at the same vertebral level in an adolescent baseball player. *Am J Sports Med*. 2003;31:606–610.
43. Herman MJ, Pizzutillo PD. Spondylolysis and spondylolisthesis in the child and adolescent. *Clin Orthop Relat Res*. 2005;NA:46–54.
44. Jackson DW, Wiltse LL, Dingeman RD, et al. Stress reactions involving the pars interarticularis in young athletes. *Am J Sports Med*. 1981;9:304–312.
45. Masci L, Pike J, Malara F, et al. Use of the one-legged hyperextension test and magnetic resonance imaging in the diagnosis of active spondylolysis. *Br J Sports Med*. 2006;40:940–946; discussion 946.
46. Ngoc-Lam N, Patel AA. Lumbar spondylolysis. *Contemp Spine Surg*. 2012;13:1–7.
47. Harvey CJ, Richenberg JL, Saifuddin A, et al. The radiological investigation of lumbar spondylolysis. *Clin Radiol*. 1998;53:723–728.
48. Gregory PL, Batt ME, Kerslake RW, et al. The value of combining single photon emission computerised tomography and computerised tomography in the investigation of spondylolysis. *Eur Spine J*. 2004; 13:503–509.
49. Radcliff KE, Kalantar SB, Reitman CA. Surgical management of spondylolysis and spondylolisthesis in athletes. *Curr Sports Med Rep*. 2009;8:35–40.
50. Sairyo K, Katoh S, Takata Y, et al. MRI signal changes of the pedicle as an indicator for early diagnosis of spondylolysis in children and adolescents. *Spine (Phila Pa 1976)*. 2006;31:206–211.
51. Campbell RSD, Grainger AJ, Hide IG, et al. Juvenile spondylolysis: a comparative analysis of CT, SPECT and MRI. *Skeletal Radiol*. 2005;34:63–73.
52. D'hemecourt PA, Gerbino PG, Micheli LJ. Back injuries in the young athlete. *Clin Sports Med*. 2000;19:663–679.
53. Kobayashi A, Kobayashi T, Kato K, et al. Diagnosis of radiographically occult lumbar spondylolysis in young athletes by magnetic resonance imaging. *Am J Sports Med*. 2013;41:169–176.
54. Wu SS, Lee CH, Chen PQ. Operative repair of symptomatic spondylolysis following a positive response to diagnostic pars injection. *J Spinal Disord*. 1999;12:10–16.
55. Kershen LM, Nacey NC, Patrie JT, et al. Accuracy and efficacy of fluoroscopy-guided pars interarticularis injections on immediate and short-term pain relief. *Skeletal Radiol*. 2016;45:1329–1335.
56. Wald JT, Geske JR, Diehn FE, et al. A practice audit of CT-guided injections of pars interarticularis defects in patients with axial low back pain: a primer for further investigation. *Pain Med*. 2014;15:745–750.
57. Micheli LJ, Curtis C. Stress fractures in the spine and sacrum. *Clin Sports Med*. 2006;52:75–88.
58. Overley SC, McAnany SJ, Andelman S, et al. Return to play in adolescent athletes with symptomatic spondylolysis without listhesis: a meta-analysis. *Glob Spine J*. 2018;8:190–197.
59. Buck JE. Direct repair of the defect in spondylolisthesis. Preliminary report. *J Bone Joint Surg Br*. 1970;52:432–437.
60. Nicol R, Scott J. Lytic spondylolysis—repair by wiring. *Spine (Phila Pa 1976)*. 1986;11:1027–1030.
61. Morscherl E, Gerber B, Fase J. Surgical treatment of spondylolisthesis by bone grafting and direct stabilization of spondylolysis by means of a hook screw. *Arch Orthop Trauma Surg*. 1984;103:175–178.
62. Gillet P, Petit M. Direct repair of spondylolysis without spondylolisthesis, using a rod-screw construct and bone grafting of the pars defect. *Spine (Phila Pa 1976)*. 1999;24:1252–1256.
63. Chin KR, Boselli K, Cairone S. Lag screw fixation of remote bilateral pedicle fractures of the fourth and fifth lumbar vertebrae after a single gunshot wound: a case report and technical pearl. *Spine J*. 2010;10:136–140.
64. Raghavan P, Christofides E. Role of teriparatide in accelerating metatarsal stress fracture healing: a case series and review of literature. *Clin Med Insights Endocrinol Diabetes*. 2012;5:39–45.
65. Rutten S, van den Bekerom MPJ, Sierevelt IN, et al. Enhancement of bone-healing by low-intensity pulsed ultrasound. *JBJS Rev*. 2016;4:1–11.

Copyright © 2020 Wolters Kluwer Health, Inc. All rights reserved.

Copyright © 2020 Wolters Kluwer Health, Inc. Unauthorized reproduction of this article is prohibited.

Copyright © 2015 by The Journal of Bone and Joint Surgery, Incorporated

A commentary by Sergio Mendoza-Lattes, MD, is linked to the online version of this article at jbjs.org.

ProDisc-C Total Disc Replacement Versus Anterior Cervical Discectomy and Fusion for Single-Level Symptomatic Cervical Disc Disease

Seven-Year Follow-up of the Prospective Randomized U.S. Food and Drug Administration Investigational Device Exemption Study

Michael E. Janssen, DO, Jack E. Zigler, MD, Jeffrey M. Spivak, MD, Rick B. Delamarter, MD, Bruce V. Darden II, MD, and Branko Kopjar, MD, MS, PhD

Background: In patients with single-level cervical degenerative disc disease, total disc arthroplasty can relieve radicular pain and preserve functional motion between two vertebrae. We compared the efficacy and safety of cervical total disc arthroplasty with that of anterior cervical discectomy and fusion (ACDF) for the treatment of single-level cervical degenerative disc disease between C3-C4 and C6-C7.

Methods: Two hundred and nine patients at thirteen sites were randomly treated with either total disc arthroplasty with ProDisc-C (n = 103) or with ACDF (n = 106). Patients were assessed preoperatively; at six weeks and three, six, twelve, eighteen, and twenty-four months postoperatively; and then annually until seven years postoperatively. Outcome measures included the Neck Disability Index (NDI), the Short Form-36 (SF-36), postoperative neurologic parameters, secondary surgical procedures, adverse events, neck and arm pain, and satisfaction scores.

Results: At seven years, the overall follow-up rate was 92% (152 of 165). There were no significant differences in demographic factors, follow-up rate, or patient-reported outcomes between groups. Both procedures were effective in reducing neck and arm pain and improving and maintaining function and health-related quality of life. Neurologic status was improved or maintained in 88% and 89% of the patients in the ProDisc-C and ACDF groups, respectively. After seven years of follow-up, thirty secondary surgical procedures had been performed in nineteen (18%) of 106 patients in the ACDF group compared with seven secondary surgical procedures in seven (7%) of 103 patients in the ProDisc-C group ($p = 0.0099$). There were no significant differences in the rates of any device-related adverse events between the groups.

Conclusions: Total disc arthroplasty with ProDisc-C is a safe and effective surgical treatment of single-level symptomatic cervical degenerative disc disease. Clinical outcomes after total disc arthroplasty with ProDisc-C were similar to those after ACDF. Patients treated with ProDisc-C had a lower probability of subsequent surgery, suggesting that total disc arthroplasty provides durable results and has the potential to slow the rate of adjacent-level disease.

Level of Evidence: Therapeutic Level I. See Instructions for Authors for a complete description of levels of evidence.

Peer Review: This article was reviewed by the Editor-in-Chief and one Deputy Editor, and it underwent blinded review by two or more outside experts. It was also reviewed by an expert in methodology and statistics. The Deputy Editor reviewed each revision of the article, and it underwent a final review by the Editor-in-Chief prior to publication. Final corrections and clarifications occurred during one or more exchanges between the author(s) and copyeditors.

Disclosure: One or more of the authors received payments or services, either directly or indirectly (i.e., via his or her institution), from a third party in support of an aspect of this work. In addition, one or more of the authors, or his or her institution, has had a financial relationship, in the thirty-six months prior to submission of this work, with an entity in the biomedical arena that could be perceived to influence or have the potential to influence what is written in this work. No author has had any other relationships, or has engaged in any other activities, that could be perceived to influence or have the potential to influence what is written in this work. The complete **Disclosures of Potential Conflicts of Interest** submitted by authors are always provided with the online version of the article.

Symptomatic cervical degenerative disc disease can be a serious condition in which the dominant symptom is pain in the neck, shoulders, and arms that is often associated with loss of function and diminished quality of life. When symptoms of nerve root compression are not relieved by nonoperative treatment, surgical decompression is the standard treatment approach[1,2].

Anterior cervical discectomy and fusion (ACDF) is a well-established and effective treatment option in which the diseased disc is surgically removed in its entirety, including clearing the anterior spinal canal and nerve root foramina of compressive disc material and osteophytes. The adjacent vertebrae are fused with an interbody spacer, and metal plates are commonly used to maintain disc height and alignment. Segment immobilization after fusion is known to lead to additional adjacent-segment biomechanical stress and degeneration, often resulting in symptoms[3-5].

Like fusion, the aim of total disc arthroplasty is to restore segmental stability after a complete discectomy and decompression. Unlike fusion, however, the goal of total disc arthroplasty is not only neural decompression, as is achieved with traditional anterior surgery, but also a stable segmental reconstruction with a device that allows for continued motion at the operatively treated disc level[6-11]. This continued motion at the operatively treated level may have protective effects on the adjacent motion segments; therefore, revision surgery should be needed less often due to less symptomatic degeneration at adjacent levels[12,13].

We report the seven-year efficacy and safety outcomes of the original patients enrolled in a U.S. Food and Drug Administration (FDA) Investigational Device Exemption (IDE) randomized controlled trial in which total disc arthroplasty with ProDisc-C was compared with ACDF for the treatment of single-level cervical degenerative disc disease.

Materials and Methods

Study Design

The FDA IDE multicenter randomized controlled trial for the ProDisc-C total disc arthroplasty system (DePuy Synthes Spine, Raynham, Massachusetts) began in the U.S. in August 2003. From August 2003 to October 2004, 228 patients at thirteen sites underwent 1:1 randomization to determine whether they would undergo either total disc arthroplasty with the ProDisc-C or ACDF. This was done with a fixed block randomization sequence of four subjects per block generated by the contract research organization and executed at each site with use of sequenced opaque sealed envelopes. The surgeon and surgical staff were not blinded to group assignment because of surgery preparation requirements. The subject remained blinded until immediately following surgery. The last randomized patient was treated in January 2005. Because nineteen patients withdrew before, or declined to undergo, surgery, a total of 209 patients underwent total disc arthroplasty (n = 103) or ACDF (n = 106).

Following FDA evaluation of the trial results, ProDisc-C received premarket approval in 2007. As part of an FDA-regulated post-approval surveillance study, the original two-year IDE study was extended, and consenting patients in the original study were followed at annual intervals until seven years postoperatively. The primary inclusion criteria were cervical degenerative disc

TABLE I Patient Demographics by Treatment Arm

	ACDF (N = 106)	ProDisc-C (N = 103)	P Value
Female *(%)*	54	55	0.8202
Age* *(yr)*	43.5 (7.15)	42.1 (8.42)	0.2274
Race *(%)*			
Caucasian	92	85	
African American	1	4	
Hispanic	5	3	
Asian American	0	5	
Other	3	3	
Body mass index* *(kg/m²)*	27.34 (5.54)	26.44 (5.32)	0.2315
Smoking status *(%)*			0.8981
Never	46	50	
Former	19	18	
Current	35	33	
Prior surgical treatment *(%)*			
Any	9	11	0.7646
Discectomy	3	4	0.7393
Intradiscal electrothermal anuloplasty	0	0	1.0000
Laminectomy	5	2	0.2332
Laminotomy	0	0	1.0000
Other	4	7	0.3786

*The values are given as the mean and standard deviation.

TABLE II Baseline Outcomes by Treatment Arm

	Score*		
	ACDF	ProDisc-C	P Value
NDI (n = 106 ACDF and 103 ProDisc-C)	52.3 (14.5)	53.9 (15.1)	0.7158
SF-36 (n = 104 ACDF and 103 ProDisc-C)			
Physical functioning (PF)	36.6 (10.0)	35.8 (10.5)	0.6069
Role limitation due to physical health (RP)	29.9 (4.5)	30.2 (5.1)	0.6610
Bodily pain (BP)	30.7 (5.7)	30.3 (6.1)	0.5933
General health (GH)	49.1 (10.6)	49.4 (9.5)	0.8315
Energy/fatigue (VT)	38.7 (9.0)	38.3 (8.7)	0.7180
Social functioning (SF)	31.8 (10.5)	31.4 (9.9)	0.7756
Role limitation due to emotional problems (RE)	37 (13.9)	38.7 (13.3)	0.3665
Emotional well-being (MH)	41 (12.1)	40.8 (11.3)	0.9041
Physical component summary (PCS)	35.2 (7.2)	34.5 (7.2)	0.5295
Mental component summary (MCS)	39.9 (12.4)	40.6 (11.7)	0.6524
VAS			
Neck pain (n = 104 ACDF and103 ProDisc-C)	65.7 (21.7)	73.0 (19.5)	0.0118
Arm pain (n = 104 ACDF and 103 ProDisc-C)	61 (26.2)	63.9 (28.8)	0.4443

*The values are given as the mean and standard deviation.

disease causing intractable debilitating radiculopathy from one vertebral segment between C3-C4 and C6-C7, unresponsiveness to nonoperative treatment for at least six weeks, and a Neck Disability Index (NDI) score of ≥15 (30%) of 50. Additional details of the study were described previously in reports of two-year[14] and five-year[15] follow-up results. No changes to the FDA-approved study design occurred in the main or post-approval studies.

Human Subjects

The initial and post-approval studies received approval from the institutional review boards at all participating sites and are registered with ClinicalTrials.gov (NCT00291018). Patients were evaluated preoperatively; at six weeks and three, six, twelve, eighteen, and twenty-four months postoperatively; and then annually until seven years postoperatively.

Primary outcome measures included the NDI, neurologic success, secondary surgical procedures (removals, revisions, reoperations, or additional fixation), and adverse events. Neurologic success was defined as maintenance or improvement of the results of sensory, motor, and reflex evaluations. Data were obtained during clinical evaluations by study investigators and research coordinators and by patient self-assessments, including the Short Form-36 (SF-36) Health Survey and visual analog scales (VASs) for neck and arm pain intensity and frequency and for patient satisfaction. Radiographic data were obtained and analyzed by radiologists at each visit.

Statistical Methods

Investigators conducted patient follow-up evaluations in person up to seven years, collecting data with use of sponsor-designed paper case report forms (CRFs) that had been verified by site-specific principal investigator surgeons. Data quality was monitored by independent study monitors to ensure that the data were true, accurate, complete, and reliable. Additionally, the FDA performed several independent audits of the source data at various investigative sites.

Differences between the two treatment groups in preoperative demographics and postoperative outcomes were analyzed with use of the Fisher exact test for the categorical variables and the t test for the continuous variables. The original IDE study had a non-inferiority statistical design using a composite end point of overall success. The study had 80% power to demonstrate non-inferiority under the one-sided type-1 error of 5%, a non-inferiority margin of 10%, and an expected success rate of 75% in both groups. The non-inferiority had been confirmed at the preplanned two-year evaluation.

For the seven-year follow-up evaluation, we used a standard superiority statistical design to evaluate differences in efficacy and safety between the two surgical procedures. Variations in outcome scores were analyzed with use of the two-year and seven-year time points. Differences at the two and seven-year time points were analyzed with use of two-way repeated-measures analysis of covariance (ANCOVA) with one fixed factor (GROUP—i.e., ProDisc-C and ACDF), one repeated factor (TIME) with two levels corresponding to two follow-up times (two and seven years), and the interaction effect between the GROUP and TIME factors. The preoperative value (e.g., preoperative NDI) of the analyzed dependent variable was used as a covariate. The dependent variables in the ANCOVA model were the changes between the two and seven-year time points along with preoperative values, respectively. This analytical model is able to adjust to the possible differences in the preoperative scores between the groups, which could result from patient attrition. We calculated the adjusted means of change values, and 95% confidence intervals (CIs) were used for the adjusted means. Differences in proportions of secondary surgical procedures on the surgical index vertebral levels were analyzed with use of the Fisher exact test. For multiple secondary surgical procedures, each patient was counted only once. The time to the patient's first secondary surgery was analyzed with use of the Kaplan-Meier estimator and tested with use of a log-rank test. Secondary surgical procedures on adjacent levels were analyzed with use of two methods. The time to the first secondary surgery on an adjacent level was analyzed with a Kaplan-Meier estimator, the survival estimates and differences in survival were tested with a log-rank test, and comparison of the rates of secondary surgical procedures on the adjacent levels between treatment groups was performed with the Andersen-Gill model. This model is based on the Cox proportional hazards model but can accommodate recurrent events. Incidence rates for the occurrence of bone bridging and device removal were calculated as the rate per person-time of exposure.

Source of Funding

The FDA IDE study was sponsored by Synthes USA HQ, West Chester, Pennsylvania. No author received compensation for the research for, or

TABLE III Differences from Baseline in Patient-Reported Outcomes by Treatment Arm and Significance of ANCOVA Model Terms

	Difference in Score Compared with Baseline*						
	ACDF		ProDisc-C				
	2 Yr	7 Yr	2 Yr	7 Yr	GROUP	TIME	GROUP* TIME
NDI	−29.77 (−34.14, −25.41)	−30.30 (−34.95, −25.66)	−32.02 (−36.22, −27.83)	−31.87 (−36.34, −27.40)	0.3563	0.9758	0.1451
SF-36							
Physical functioning (PF)	9.93 (7.62, 12.23)	9.89 (7.61, 12.18)	12.29 (10.10, 14.47)	10.99 (8.82, 13.16)	0.2211	0.2604	0.4139
Role limitation due to physical health (RP)	15.34 (12.52, 18.16)	15.24 (12.35, 18.12)	15.31 (12.64, 17.98)	16.03 (13.29, 18.77)	0.8257	0.8355	0.6803
Role limitation due to emotional problems (RE)	9.80 (7.02, 12.58)	8.01 (4.94, 11.08)	10.26 (7.63, 12.89)	9.67 (6.76, 12.58)	0.5293	0.4496	0.6094
Energy/ fatigue (VT)	10.63 (7.98, 13.29)	10.21 (7.41, 13.01)	11.89 (9.37, 14.41)	12.43 (9.78, 15.09)	0.309	0.1256	0.5686
Emotional well-being (MH)	7.34 (4.73, 9.96)	5.94 (3.03, 8.85)	7.69 (5.21, 10.17)	7.59 (4.84, 10.35)	0.5478	0.1664	0.5069
Social functioning (SF)	15.56 (12.89, 18.24)	15.02 (12.17, 17.86)	15.49 (12.95, 18.03)	15.64 (12.94, 18.34)	0.8705	0.1246	0.7072
Bodily pain (BP)	14.28 (11.59, 16.97)	15.94 (13.13, 18.74)	17.23 (14.68, 19.78)	16.05 (13.39, 18.70)	0.3563	0.9758	0.1451
General health (GH)	0.84 (−1.29, 2.97)	0.64 (−1.76, 3.05)	1.61 (−0.41, 3.63)	0.21 (−2.07, 2.49)	0.9043	0.0679	0.4095
Physical component summary (PCS)	10.91 (8.49, 13.32)	12.09 (9.70, 14.48)	13.12 (10.84, 15.41)	12.24 (9.98, 14.51)	0.4238	0.8727	0.1984
Mental component summary (MCS)	9.11 (6.32, 11.89)	6.93 (4.11, 9.75)	8.58 (5.94, 11.22)	8.93 (6.26, 11.60)	0.6635	0.2568	0.2004
VAS							
Arm pain	−40.15 (−46.28, −34.02)	−38.83 (−45.40, −32.25)	−40.67 (−46.48, −34.86)	−40.72 (−46.95, −34.49)	0.7484	0.9437	0.7725
Neck pain	−42.73 (−49.16, −36.30)	−42.88 (−49.75, −36.02)	−44.73 (−50.83, −38.64)	−45.67 (−52.18, −39.16)	0.5344	0.9962	0.8824

*The values are given as the adjusted means with the 95% CI.

preparation of, this manuscript. DePuy Synthes Spine provided full access to trial data. All analyses for this study were designed, performed, and validated by a sponsor-independent biostatistician who was not involved in the original IDE study.

Results

Follow-up Rates: Overall and by Study Arm

Of 209 patients enrolled, twenty-eight did not participate in long-term follow-up, ten withdrew, and six died. Among patients eligible for the seven-year visit, the follow-up rate was 92% (seventy-nine of eighty-six) in the ProDisc-C group and 92% (seventy-three of seventy-nine) in the ACDF group (Fig. 1).

Demographics

There were no differences between the ProDisc-C and ACDF groups with regard to any of the analyzed demographic factors (Table I).

Clinical and Patient-Reported Outcomes

The baseline NDI was high, indicating the severity of the symptoms of the cervical disease. The baseline VAS score for neck pain was higher in the ProDisc-C group than in the ACDF group (73.0 and 65.7, respectively, $p = 0.0118$). The two groups did not differ at baseline with regard to any other outcome measures (Table II).

Table III shows adjusted means and their confidence intervals as well as the results of ANCOVA statistical testing for the patient-reported outcomes. All outcomes except for the SF-36 general health domain were improved, compared with the preoperative status, at two years in both study arms ($p < 0.05$), and those improvements were maintained at seven years ($p < 0.05$). There was no significant difference between the ProDisc-C and

TABLE IV Neurologic Success*

	2 Yr	7 Yr
ACDF *(no. [%])*	81/92 (88%)	56/63 (89%)
ProDisc-C *(no. (%))*	90/99 (91%)	64/73 (88%)
P value	0.3892	1.0000

*Neurologic success was defined as the maintenance or improvement of the results of the sensory, motor, and reflex evaluations.

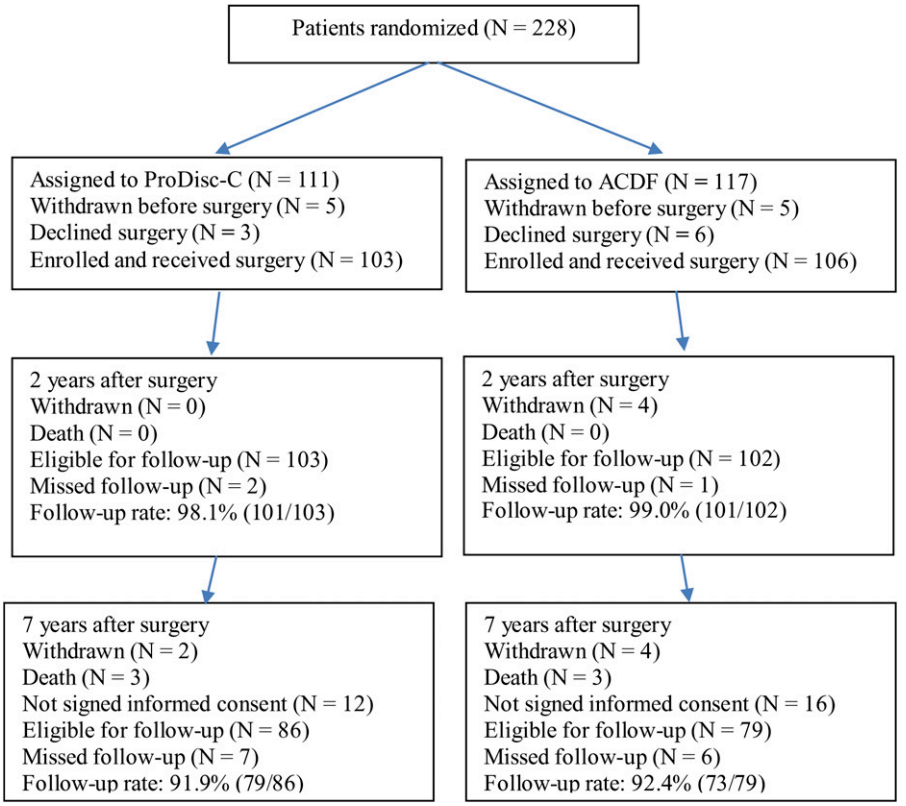

Fig. 1
Patient flowchart. "Withdrew" indicates that the patient signed the informed consent form but later withdrew. "Missed follow-up" means the patient was lost to follow-up.

ACDF groups with regard to the extent of the improvement in any outcome variable (GROUP effect: $p > 0.05$ for all variables). Furthermore, there was no difference in the extent of improvement in any outcome variables from two to seven years postoperatively (TIME effect: $p > 0.05$). Finally, there were no differences in the time course changes between the groups at two and seven years (GROUP*TIME interaction: $p > 0.05$) for any outcome variable.

Satisfaction with Surgery

At two years, the mean score on the VAS for satisfaction with the result of the surgery (with 100 mm representing highest satisfaction) was 83.39 ± 24.84 mm in the ProDisc-C group and 79.99 ± 28.04 mm in the ACDF group ($p = 0.4030$). At seven years, both groups again reported a high level of satisfaction: 85.81 ± 23.97 mm in the ProDisc-C group and 81.81 ± 29.48 mm in the ACDF group ($p = 0.3906$).

Neurologic Outcomes

Neurologic outcomes were measured among patients who had not had secondary surgery. At seven years, the rates of neurologic success (improvement or maintenance) were 88% and 89% in the ProDisc-C and ACDF groups, respectively ($p = 1.000$). For comparison, the rates of neurologic success at two years were 91% in the ProDisc-C group and 88% in the ACDF group ($p = 0.3892$) (Table IV).

Secondary Surgical Procedures

At seven years, thirty secondary surgical procedures had been performed in nineteen (18%) of the 106 patients in the ACDF group compared with seven secondary surgical procedures in seven (7%) of the 103 patients in the ProDisc-C group ($p = 0.0201$). Figure 2 shows the mean cumulative function of risk for secondary surgery, which at seven years was approximately 3.7 times higher in the ACDF group than in the ProDisc-C group (Wald $p = 0.0099$).

Nineteen secondary surgical procedures in sixteen patients (15%) in the ACDF group were performed at the index vertebral level, whereas six secondary surgical procedures in six patients (6%) in the ProDisc-C group were done at the index level ($p = 0.0410$). Of the six secondary surgical procedures at the index level in the six patients in the ProDisc-C group, five consisted of device removal with conversion to fusion and one involved foraminotomy and cervical fusion with posterior stabilization and the ProDisc-C left in place. Of the nineteen secondary surgical procedures at the index level in the sixteen patients in the ACDF group, eight included only the index level (three supplemental fixation procedures, one plate removal, and four revisions) and eleven included both the index level and adjacent levels (nine ACDFs at adjacent levels, one posterior fusion, and one implantation of a ProDisc-C at the adjacent level). Figure 3 shows Kaplan-Meier survival estimates for

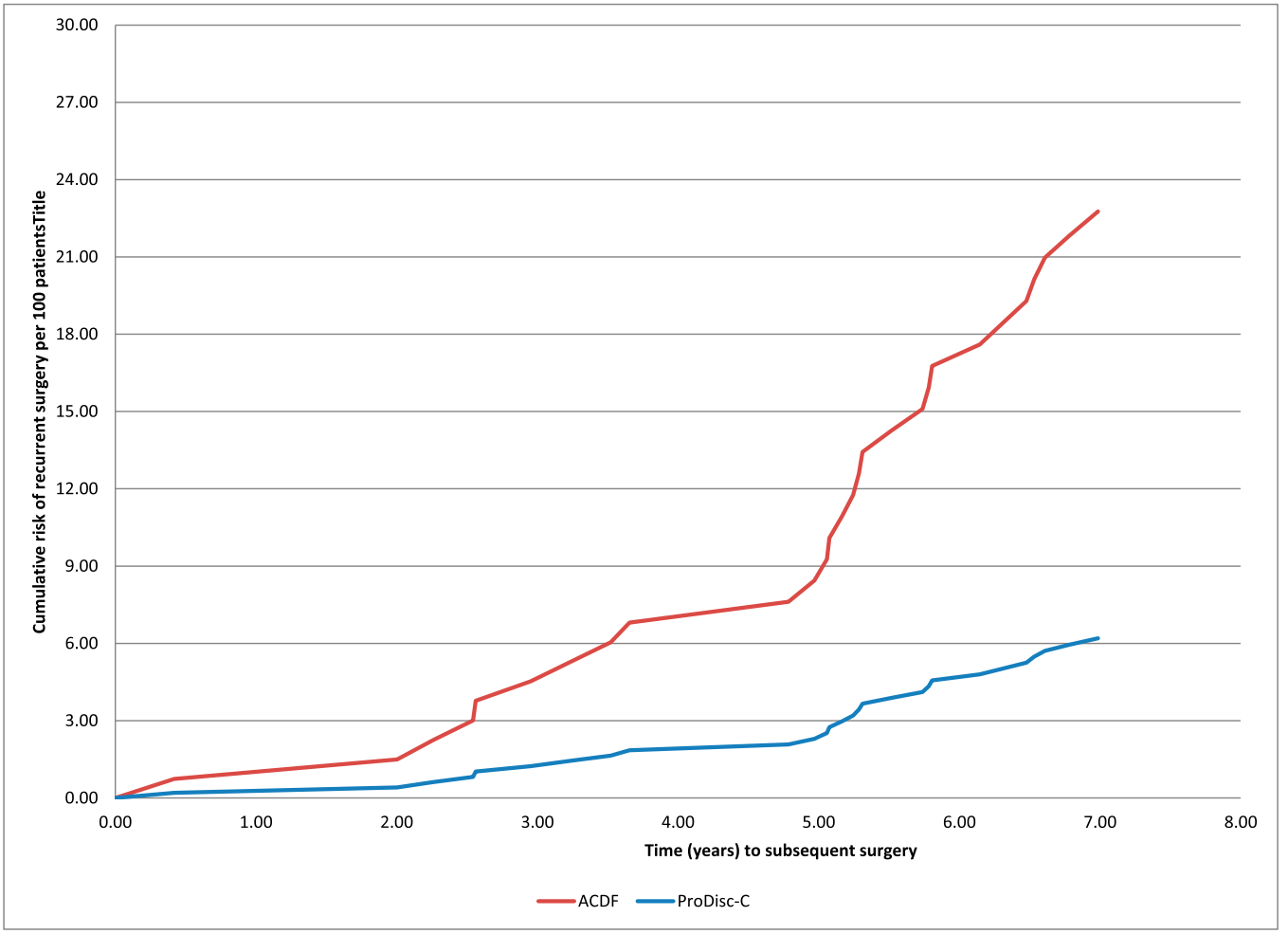

Fig. 2
Mean cumulative function of risk for secondary surgical procedures.

the time to a patient's first secondary surgery at the index level in each group. The time period before the first reoperation and the reoperation-free rate were greater in the ProDisc-C group than in the ACDF group (log-rank p = 0.0221). The conditional incidence rate ratio for secondary surgery at the index level was 3.09 (95% CI = 1.27 to 8.45, p = 0.0112).

In the ProDisc-C group, six surgical procedures involving adjacent levels were done in six patients, compared with twenty-two surgical procedures involving adjacent levels in thirteen patients in the ACDF group. The log-rank test p value for the time to first surgery at the adjacent level was 0.0837, and the hazard ratio for secondary surgery events at the adjacent level was 3.624 (p = 0.0103).

Radiographic Outcomes

At seven years, 11% (eight) of seventy-one patients in the ProDisc-C group had bone bridging on radiographs with loss of motion at the index level. The cumulative rate of bone bridging was linear, with the rate increasing as the time period after surgery increased. The incidence rate of bone-bridging was 1.27 (95% CI = 0.63 to 2.63) per 100 person-years (the ratio of the number of patients with bridging bone at seven years times 100, divided by the number of follow-up years of all patients in the ProDisc-C group during which bridging bone could have occurred [632.43]).

At seven years, the mean flexion-extension range of motion (and standard deviation) at the index level was 8.12° ± 5.91° in the ProDisc-C group compared with 0.66° ± 0.58° in the ACDF group (p < 0.0001).

Adverse Events

Table V shows device-related adverse events reported during the seven years. Altogether, forty-eight adverse events were reported in thirty (28%) of the 106 patients in the ACDF group and forty-one adverse events were reported in twenty-eight (27%) of the 103 patients in the ProDisc-C group. The most commonly reported adverse event was neck pain (isolated or with pain in the shoulders and arms). There were no significant differences between groups with regard to any category of adverse event or with regard to the proportion of patients with any adverse event at all (p = 0.8783).

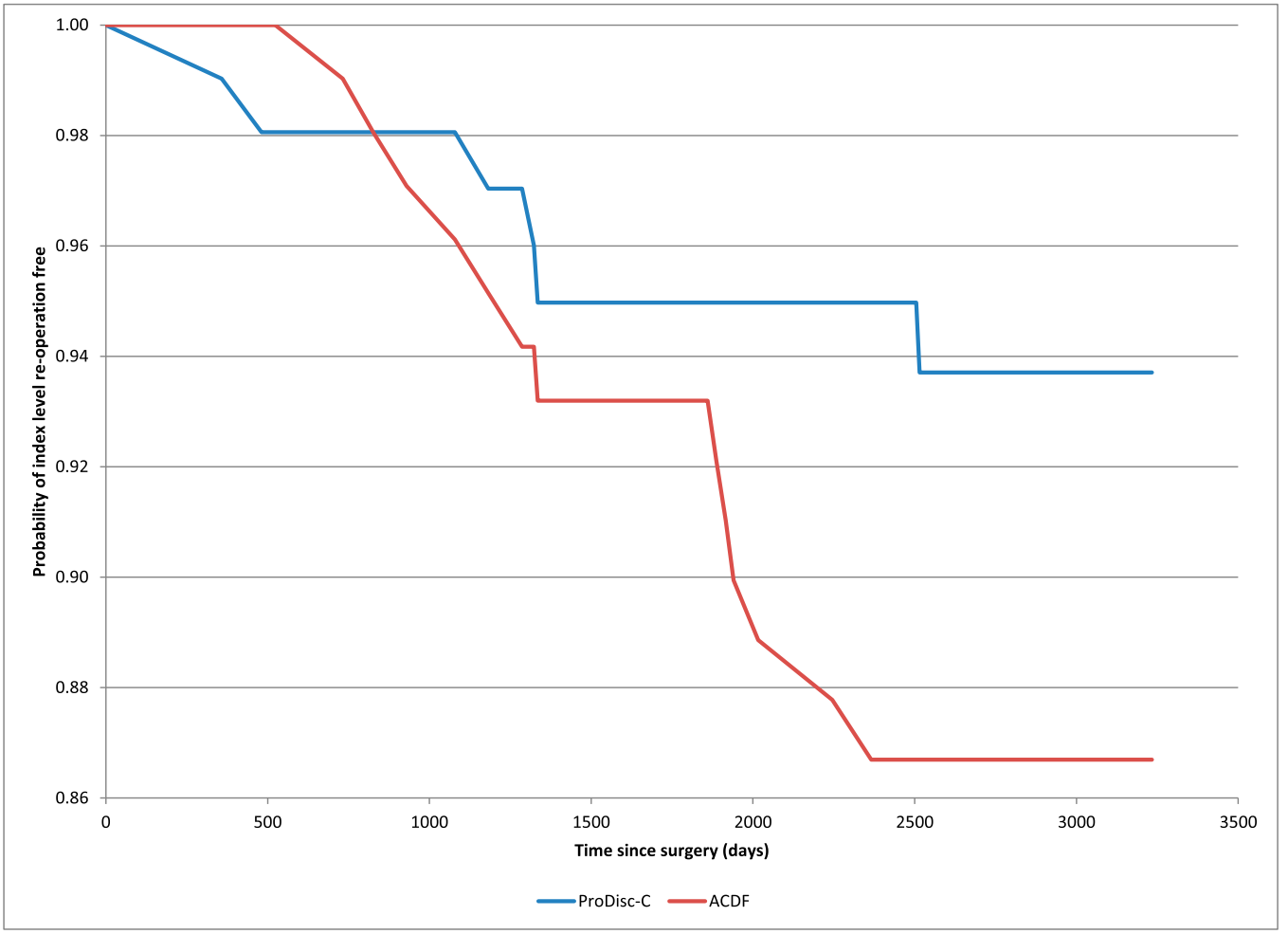

Fig. 3
Kaplan-Meier device survival curve for index level reoperation-free experience.

Medication Usage

Preoperatively, strong (Schedule-2) or weak (Schedule-3) narcotic pain medications were being used by 46% (forty-nine) of the 106 patients in the ACDF group and 48% (forty-nine) of the 103 in the ProDisc-C group ($p > 0.05$). Muscle relaxants were being used by 22% (twenty-three) of the 106 patients in the ACDF group and 19% (twenty) of the 103 in the ProDisc-C group ($p > 0.05$). The use of these medications decreased considerably from baseline over the postoperative period in both groups. At seven years, 12% (nine) of the seventy-six patients in the ProDisc-C group and 14% (ten) of the seventy-one in the ACDF group had taken strong narcotics in the week before their follow-up visit ($p > 0.05$). (Information was not available for all subjects.) Additionally, 15% (twelve) of the seventy-nine patients in the ProDisc-C group and 11% (eight) of the seventy-three in the ACDF group had taken muscle relaxants in the week before their follow-up visit ($p > 0.05$).

Discussion

Although cervical total disc arthroplasty devices have been available in the U.S. for several years, ACDF remains the treatment of choice for cervical degenerative disc disease[16]. This is due in part to surgeons' uncertainty about the long-term outcomes of cervical total disc arthroplasty compared with their perception of long-term clinical success with ACDF[17].

To our knowledge, our study is the first and most comprehensive evaluation of the long-term efficacy and safety of cervical total disc arthroplasty. We followed patients enrolled in the original FDA IDE randomized controlled trial for seven years. Our results through these seven years demonstrate that total disc arthroplasty with ProDisc-C continues to be a safe and effective surgical treatment for patients with single-level cervical degenerative disc disease refractory to nonoperative treatment. The study design (which minimized potential investigator bias), the equivalence of the baseline demographics and clinical characteristics of the two groups (indicating excellent randomization), and the high follow-up rates in both the ProDisc-C and the ACDF group (98% and 99% at two years, 92% and 92% at seven years, respectively) result in Level-I data. The high overall follow-up rate of 92% achieved at seven years meets the criteria for a high level of evidence

TABLE V Device-Related Adverse Events by Treatment Arm During the Seven Years of Follow-up

	ProDisc-C		ACDF		
	No. of Events	No. of Patients	No. of Events	No. Patients	P Value
Any adverse event	41	28	48	30	0.8783
Adjacent-level degenerative disc disease or degenerative joint disease changes	1	1	2	2	1.0000
Cardiovascular	1	1	0	0	0.4928
Dysphagia	0	0	2	2	0.4977
Headache	7	6	1	1	0.0627
Musculoskeletal	2	2	6	6	0.2799
Musculoskeletal: neck spasms	1	1	0	0	0.4928
Neurologic	0	0	1	1	1.0000
Numbness					
Index-level related	2	2	2	2	1.0000
Non-index-level related	3	2	1	1	0.6178
Ossification	1	1	0	0	0.4928
Other	1	1	2	2	1.0000
Pain					
Back and lower extremities	1	1	1	1	1.0000
Incision site	1	1	0	0	0.4928
Neck	7	5	7	7	0.7680
Neck and other	0	0	1	1	1.0000
Neck and shoulder	2	2	2	2	1.0000
Neck and upper extremities	2	2	3	3	1.0000
Neck and upper extremities with numbness	2	2	2	2	1.0000
Shoulder	2	2	2	2	1.0000
Upper extremities	0	0	2	2	0.4977
Upper extremities with numbness	1	1	0	0	0.4928
Surgery for device-related events					
Index level	2	2	5	5	0.4455
Other	1	1	6	6	0.1190
Other wound issues	1	1	0	0	0.4928

regarding the safety and efficacy of cervical total disc arthroplasty with ProDisc-C.

Efficacy outcomes were similar between the two treatment groups. The amount of improvement in NDI, VAS pain, and SF-36 Physical Component Summary (PCS) and Mental Component Summary (MCS) scores at two[14] and seven years exceeds reported values for minimal clinical significant differences in these measures[18]. It is reasonable to conclude that total disc arthroplasty with ProDisc-C and ACDF are both effective and do not differ in terms of patient-reported outcomes of pain, function, and health-related quality of life.

Secondary surgery is an important clinical event with substantial clinical and financial burdens for the patient as well as additional cost for the payor[6,19]. Studies have suggested that total disc arthroplasty is more cost-effective than ACDF, primarily because of the lower rate of secondary surgical procedures[13,20,21]. We found that ProDisc-C was superior to ACDF in terms of the rate of secondary surgical procedures involving the surgical index level.

Protecting adjacent segments and preventing symptoms of adjacent-segment disease are hypothesized to be the primary advantages of total disc arthroplasty over ACDF[7], but this had not been demonstrated after one to two years of follow-up[7-9,22-25]. In our study with longer follow-up, total disc arthroplasty with ProDisc-C appeared to protect the adjacent segments. There were significantly more surgical procedures involving adjacent levels in the ACDF group than in the ProDisc-C group. Surgeon bias in terms of the decision for adjacent-level fusion extension in patients with ACDF may have played a role. The rate of total disc arthroplasty device removal was low; only five of 103 devices were explanted throughout the seven years.

Overall, it appears that total disc arthroplasty with ProDisc-C has similar clinical and patient outcomes, has a higher device survival rate, and is followed by fewer secondary surgical

procedures than ACDF. The overall rate of adverse events was similar between the groups.

There are limitations of our study. First, our data reflect experience with only one cervical total disc arthroplasty device (ProDisc-C) and thus cannot be generalized to other total disc arthroplasty devices. Second, our data were derived from selected patients who met specific inclusion and exclusion criteria for the randomized controlled trial. Real-world patient populations may differ from the patients enrolled in the randomized controlled trial. Third, all of the ProDisc-C procedures performed in the patients in the IDE study represented the earliest learning curve for each investigator surgeon. Additional surgical experience as well as the impact of a formal standardized training program after the FDA approval may lead to improved outcomes.

In conclusion, both ACDF and cervical total disc arthroplasty with ProDisc-C result in significant long-term improvements in relevant symptoms and clinical, functional, and health-related general health outcomes in patients with single-level cervical degenerative disc disease refractory to nonoperative treatment. At seven years postoperatively, all outcomes were similar in the two cohorts. However, total disc arthroplasty with ProDisc-C was associated with a lower risk of secondary surgery at both the index and adjacent vertebral levels. ■

NOTE: The authors thank Karen K. Anderson, BS, for her assistance with manuscript editing and preparation.

Michael E. Janssen, DO
Center for Spinal Disorders/Scientific Education and Research Institute,
9005 Grant Street,
Suite 200, Thornton, CO 80229

Jack E. Zigler, MD
Texas Back Institute,
6020 West Parker Road,
Suite 200, Plano, TX 75093

Jeffrey M. Spivak, MD
Department of Orthopaedic Surgery,
NYU Hospital for Joint Diseases,
301 East 17th Street,
New York, NY 10003

Rick B. Delamarter, MD
The Spine Institute,
2811 Wilshire Boulevard,
Suite 850,
Santa Monica, CA 90403

Bruce V. Darden II, MD
OrthoCarolina Spine Center,
2001 Randolph Road,
Charlotte, NC 28207

Branko Kopjar, MD, MS, PhD
Department of Health Services,
University of Washington,
4333 Brooklyn Avenue N.E.,
Room 14-315,
Seattle, WA 98195-9455.
E-mail address: brankok@u.washington.edu

References

1. Albert TJ, Murrell SE. Surgical management of cervical radiculopathy [Review]. J Am Acad Orthop Surg. 1999 Nov-Dec;7(6):368-76.

2. Boyce RH, Wang JC. Evaluation of neck pain, radiculopathy, and myelopathy: imaging, conservative treatment, and surgical indications. Instr Course Lect. 2003;52:489-95.

3. Ragab AA, Escarcega AJ, Zdeblick TA. A quantitative analysis of strain at adjacent segments after segmental immobilization of the cervical spine. J Spinal Disord Tech. 2006 Aug;19(6):407-10.

4. Hilibrand AS, Carlson GD, Palumbo MA, Jones PK, Bohlman HH. Radiculopathy and myelopathy at segments adjacent to the site of a previous anterior cervical arthrodesis. J Bone Joint Surg Am. 1999 Apr;81(4):519-28.

5. Matsunaga S, Kabayama S, Yamamoto T, Yone K, Sakou T, Nakanishi K. Strain on intervertebral discs after anterior cervical decompression and fusion. Spine (Phila Pa 1976). 1999 Apr 1;24(7):670-5.

6. Auerbach JD, Anakwenze OA, Milby AH, Lonner BS, Balderston RA. Segmental contribution toward total cervical range of motion: a comparison of cervical disc arthroplasty and fusion. Spine (Phila Pa 1976). 2011 Dec 1;36(25): E1593-9.

7. Shi R, Li J, Liu H, Ding C, Hu T, Li T, Gong Q. Clinical comparison of 2 implantation systems for single-level cervical disk replacement. Orthopedics. 2014 Feb;37(2): e161-8.

8. Yin S, Yu X, Zhou S, Yin Z, Qiu Y. Is cervical disc arthroplasty superior to fusion for treatment of symptomatic cervical disc disease? A meta-analysis. Clin Orthop Relat Res. 2013 Jun;471(6):1904-19. Epub 2013 Feb 07.

9. Yang B, Li H, Zhang T, He X, Xu S. The incidence of adjacent segment degeneration after cervical disc arthroplasty (CDA): a meta analysis of randomized controlled trials [Review]. PLoS One. 2012;7(4):e35032. Epub 2012 Apr 25.

10. Mummaneni PV, Amin BY, Wu JC, Brodt ED, Dettori JR, Sasso RC. Cervical artificial disc replacement versus fusion in the cervical spine: a systematic review comparing long-term follow-up results from two FDA trials. Evid Based Spine Care J. 2012 Feb;3(S1):59-66.

11. Kim HJ, Kelly MP, Ely CG, Dettori JR, Riew KD. The risk of adjacent-level ossification development after surgery in the cervical spine: are there factors that affect the risk? A systematic review. Spine (Phila Pa 1976). 2012 Oct 15;37(22)(Suppl): S65-74.

12. Wang Q, Cheng H, Mao Z, Qi X, Zhang M, Chen Y. Clinical and radiographic results after treatment of cervical degenerative disc disease with the bryan disc prosthesis: a prospective study with 2-year follow-up. Acta Orthop Belg. 2011 Dec;77(6):809-15.

13. Blumenthal SL, Ohnmeiss DD, Guyer RD, Zigler JE. Reoperations in cervical total disc replacement compared with anterior cervical fusion: results compiled from multiple prospective food and drug administration investigational device exemption trials conducted at a single site. Spine (Phila Pa 1976). 2013 Jun 15;38 (14):1177-82.

14. Murrey D, Janssen M, Delamarter R, Goldstein J, Zigler J, Tay B, Darden B. Results of the prospective, randomized, controlled multicenter Food and Drug Administration investigational device exemption study of the ProDisc-C total disc replacement versus anterior discectomy and fusion for the treatment of 1-level symptomatic cervical disc disease. Spine J. 2009 Apr;9(4):275-86. Epub 2008 Sep 06.

15. Zigler JE, Delamarter R, Murrey D, Spivak J, Janssen M. ProDisc-C and anterior cervical discectomy and fusion as surgical treatment for single-level cervical symptomatic degenerative disc disease: five-year results of a Food and Drug Administration study. Spine (Phila Pa 1976). 2013 Feb 1;38(3):203-9.

16. Munigangaiah S, McCabe JP. Cervical disc replacement: A systematic review. Int J Clin Med. 2013;4(7A):34-9.

17. Bhatnagar R, Bergin P, Matteini LE, Yu W, O'Brien JR. Cervical disc arthroplasty. Curr Orthop Pract. 2010;21(3):306-9.

18. Carreon LY, Glassman SD, Campbell MJ, Anderson PA. Neck Disability Index, short form-36 physical component summary, and pain scales for neck and arm pain: the minimum clinically important difference and substantial clinical benefit after cervical spine fusion. Spine J. 2010 Jun;10(6):469-74. Epub 2010 Apr 01.

19. Rajaee SS, Bae HW, Kanim LE, Delamarter RB. Spinal fusion in the United States: analysis of trends from 1998 to 2008. Spine (Phila Pa 1976). 2012 Jan 1;37 (1):67-76.

20. Radcliff K, Zigler JD, Zigler JE. Costs of cervical disc replacement versus anterior cervical discectomy and fusion for treatment of single-level cervical disc disease: An analysis of the blue health intelligence database for acute and long-term costs and complications. Spine J. 2013;13(9S):S6.

21. Delamarter RB, Zigler J. Five-year reoperation rates, cervical total disc replacement versus fusion, results of a prospective randomized clinical trial. Spine (Phila Pa 1976). 2013 Apr 20;38(9):711-7.

22. Boselie TF, Willems PC, van Mameren H, de Bie R, Benzel EC, van Santbrink H. Arthroplasty versus fusion in single-level cervical degenerative disc disease [Review]. Cochrane Database Syst Rev. 2012;9:CD009173. Epub 2012 Sep 12.

23. Fallah A, Akl EA, Ebrahim S, Ibrahim GM, Mansouri A, Foote CJ, Zhang Y, Fehlings MG. Anterior cervical discectomy with arthroplasty versus arthrodesis for single-level cervical spondylosis: a systematic review and meta-analysis [Review]. PLoS One. 2012;7(8):e43407. Epub 2012 Aug 17.

24. Cepoiu-Martin M, Faris P, Lorenzetti D, Prefontaine E, Noseworthy T, Sutherland L. Artificial cervical disc arthroplasty: a systematic review [Review]. Spine (Phila Pa 1976). 2011 Dec 1;36(25):E1623-33.

25. Zechmeister I, Winkler R, Mad P. Artificial total disc replacement versus fusion for the cervical spine: a systematic review [Review]. Eur Spine J. 2011 Feb;20 (2):177-84. Epub 2010 Oct 10.

Updated Return-to-Play Recommendations for Collision Athletes After Cervical Spine Injury: A Modified Delphi Consensus Study With the Cervical Spine Research Society

Gregory D. Schroeder, MD*
Jose A. Canseco, MD, PhD*
Parthik D. Patel, MD*
Alan S. Hilibrand, MD*
Christopher K. Kepler, MD, MBA*
Srdjan M. Mirkovic, MD‡
Robert G. Watkins, III, MD§
Andrew Dossett, MD¶
Andrew C. Hecht, MD‖
Alexander R. Vaccaro, MD, PhD, MBA*

*Rothman Orthopaedic Institute at Thomas Jefferson University Hospital, Philadelphia, Pennsylvania; ‡Northwestern Orthopaedic Institute, NorthShore University HealthSystem, Chicago, Illinois; §Marina Spine Center, Marina del Rey, California; ¶The Carrell Clinic Orthopedic and Sports Medicine, Dallas, Texas; ‖Department of Orthopaedic Surgery, Icahn School of Medicine at Mount Sinai, Mount Sinai Hospital, New York, New York

Correspondence:
Jose A. Canseco, MD, PhD,
Department of Orthopaedic Surgery,
Rothman Orthopaedic Institute at
Thomas Jefferson University Hospital,
925 Chestnut St, 5th Floor,
Philadelphia, PA 19107, USA.
Email: jose.canseco@rothmanortho.com

Received, March 23, 2020.
Accepted, May 31, 2020.
Published Online, July 28, 2020.

Copyright © 2020 by the
Congress of Neurological Surgeons

BACKGROUND: Previous studies have attempted to establish return-to-play (RTP) guidelines in collision sport athletes after cervical spine injury; however, recommendations have been limited by scant high-quality evidence and basic consensus survey methodologies.
OBJECTIVE: To create relevant clinical statements regarding management in collision sport athletes after cervical spine injury, and establish consensus RTP recommendations.
METHODS: Following the modified Delphi methodology, a 3 round survey study was conducted with spine surgeons from the Cervical Spine Research Society and National Football League team physicians in order to establish consensus guidelines and develop recommendations for cervical spine injury management in collision sport athletes.
RESULTS: Our study showed strong consensus that asymptomatic athletes without increased magnetic resonance imaging (MRI) T2-signal changes following 1-/2- level anterior cervical discectomy and fusion (ACDF) may RTP, but not after 3-level ACDF (84.4%). Although allowed RTP after 1-/2-level ACDF was noted in various scenarios, the decision was contentious. No consensus RTP for collision athletes after 2-level ACDF was noted. Strong consensus was achieved for RTP in asymptomatic athletes without increased signal changes and spinal canal diameter >10 mm (90.5%), as well as those with resolved MRI signal changes and diameter >13 mm (81.3%). No consensus was achieved in RTP for cases with pseudarthrosis following ACDF. Strong consensus supported a screening MRI before sport participation in athletes with a history of cervical spine injury (78.9%).
CONCLUSION: This study provides modified Delphi process consensus statements regarding cervical spine injury management in collision sport athletes from leading experts in spine surgery, sports injuries, and cervical trauma. Future research should aim to elucidate optimal timelines for RTP, as well as focus on prevention of injuries.

KEY WORDS: Cervical spine, Trauma, Collision, Sports, Return to play, Consensus, Guidelines

Neurosurgery 87:647–654, 2020 DOI:10.1093/neuros/nyaa308 www.neurosurgery-online.com

Collision sports have an inherent risk of injury, with estimates reporting 9% to 15% of over 12 000 new cases of spine injuries per year in the United States attributable to sports.[1-6] Based on recent estimates by the U.S. Census Bureau and the U.S. Bureau of Labor Statistics, almost 4 million Americans play football on an average day, and about 80% are between 15 and 24 yr old.[7,8] Spine injuries associated with football are common, with studies suggesting between 7% and 10% of injuries in National Football League (NFL)-level athletes involve the head/neck/spine—not including concussions.[3,9-11] Moreover, estimates suggest 35% to 49% of collision sport spine injuries affect the cervical spine, resulting in nerve injuries (46%), muscle injuries (22%), disc injuries (6%), contusions (2%), and fractures (2%), among

ABBREVIATIONS: ACDF, anterior cervical discectomy and fusion; **AEs,** athlete-exposures; **CSRS,** Cervical Spine Research Society; **MRI,** magnetic resonance imaging; **NFL,** National Football League; **RTP,** return-to-play

Supplemental digital content is available for this article at www.neurosurgery-online.com.

Downloaded from https://academic.oup.com/neurosurgery/article/87/4/647/5876000 by Bora Laskin Law Library user on 30 November 2020

others; and a majority affect individuals under 30 yr old.[1,3,10,12-14] Furthermore, recent reports for NFL-level and college-level football athletes suggest axial skeleton in-game injury incidence rates of 3.55/1000 athlete-exposures (AEs) and 148.26/100 000 AEs, respectively.[4,10]

Over the years, recommendations have been published to direct return-to-play (RTP) decisions in collision sports with respect to a variety of injuries to the cervical spine. Given the complexity and functional consequences of these injuries, prospective, randomized, controlled trials are not plausible; as a result, most available guidelines for RTP derive from systematic reviews, expert opinion, meta-analyses, and case series or reports.[15-28] However, consensus RTP recommendations have yet to be universally established.[29] The purpose of this study was to utilize a modified Delphi process with the Cervical Spine Research Society (CSRS) to formulate actionable statements and establish updated consensus RTP recommendations for providers caring for collision athletes with cervical spine injuries.

METHODS

A modified Delphi method study was conducted using CSRS members and NFL team physicians to build consensus on RTP recommendations after cervical spine injury in collision sports athletes.[30,31] A first-round anonymous online survey composed of 14 clinical scenarios and 38 related questions involving cervical spine injuries in football players was developed based on literature review and expert opinion (**Supplemental Digital Content 1**).[1,30,31] In November 2019, the survey was sent to all CSRS members. Results were reviewed by CSRS members and NFL team physicians, and thirteen consensus statements were developed.[31] These statements were administered to attendees at the CSRS annual meeting in November 2019 (second-round). Voting abstentions were not counted for consensus tallying purposes.[32,33] Results of this second survey were used to generate consensus recommendations based on the following levels: simple majority (50.1%-59%, no consensus), super majority (60%-70%, weak consensus), super majority (71%-94%, strong consensus), and unanimous (95%-100%, strongest consensus). To address concerns with RTP for professional athletes after 2-level anterior cervical discectomy and fusion (ACDF) based on second-round data, a third round online anonymous survey was sent to a focused group of NFL-affiliated spine surgeons. A Fisher exact test was performed to compare data between professional and nonprofessional sports affiliated physicians where appropriate, with significance established at $P < .05$. This clinician survey study was exempt from Institutional Review Board review.

RESULTS

Initial Cervical Trauma Survey

First round responses were received from 48 expert spine surgeon members of the CSRS: 87.5% were orthopaedic surgeons (n = 42) and 12.5% were neurosurgeons (n = 6). Table 1 shows characteristics of the initial expert panel. For details of the results of the initial survey, see **Supplemental Digital Content 2**.

TABLE 1. Expert Panel Demographics for First Round Questionnaire

Initial expert panel demographics (n = 48)	Number of experts
Specialty	
Orthopaedic spine surgery	42
Neurosurgery	6
Years in practice	
<5 yr	3
5-10 yr	5
10-20 yr	19
>20 yr	21
Team physician (NCAA or NFL)	
Yes	12
No	36

NCAA = National Collegiate Athletic Association; NFL = National Football League.

RTP Consensus Recommendations

Upon analysis of initial survey results, 13 clinical recommendations were developed and voted upon by 95 attendees of the 2019 CSRS Annual Meeting, with an average engagement of 71%. Of these participants, 64/95 identified as orthopaedic spine surgeons and 3/95 identified as "other", with 28/95 participants not identifying their subspecialty. Additionally, 17/95 participants identified as actively caring for professional collision athletes, and 63/95 identified as having involvement in the care of competitive collision athletes. From the 13 recommendations surveyed, 8 statements achieved strong consensus, 3 achieved weak consensus, and 2 achieved no consensus. No significant difference in responses was noted between professional and nonprofessional sports team-affiliated physicians.

RTP Recommendations in Collision Sport Athletes Based on Severity of Cervical Canal Stenosis

Regarding collision athletes after an initial episode of transient paralysis from a cervical spine injury, 90.5% (strong consensus) of participants agreed that RTP was recommended once symptoms have subsided, there are no T2 magnetic resonance imaging (MRI) changes and spinal canal diameter is >10 mm; if canal diameter is in the absolute stenosis range, RTP should be considered on an individual basis. Additionally, for athletes in a similar case but with initial changes on T2 sequence MRI, almost 81.3% (strong consensus) of participants noted that RTP was allowed once MRI changes resolved only if spinal canal diameter is >13 mm; for those in the relative stenosis range RTP should be approached on a case-by-case basis, and those with absolute stenosis should not be allowed to RTP. Furthermore, 68.3% (weak consensus) of participants noted that for athletes that have persistent MRI changes, individual evaluation for RTP can be considered only if spinal canal diameter is >13 mm, otherwise RTP should be contraindicated. Of note, only one statement achieved a simple majority without consensus for a disagreement, with 50.7% of surgeons (38.5% of those affiliated

Downloaded from https://academic.oup.com/neurosurgery/article/87/4/647/5876000 by Bora Laskin Law Library user on 30 November 2020

TABLE 2. RTP Guidelines Based on Severity of Cervical Stenosis

Statement	All physicians % (n)	Level of recommendation	% Agreement of professional sports team-affiliated physicians[a] % (n)	*P* value[b]
RTP guidelines in collision athletes based on severity of cervical stenosis				
Following an episode of transient paralysis, asymptomatic athletes with NO T2-signal change and a spinal canal diameter >10 mm are allowed to RTP, but those with a canal diameter <10 mm should be taken on a case-by-case basis.	**Agree: 90.5 (57)** Disagree: 9.5 (6)	Super majority, strong consensus	85.7 (12/14) Strong consensus	.64
Following an episode of transient paralysis, asymptomatic athletes with RESOLVED T2-signal changes and a spinal canal diameter >13 mm are allowed to RTP; those with a canal diameter between 10 and 13 mm should be considered on a case-by-case basis, and those with a canal diameter <10 mm should not RTP.	**Agree: 81.25 (52)** Disagree: 18.75 (12)	Super majority, strong consensus	66.7 (10/15) Weak consensus	.10
Following an episode of transient paralysis, for asymptomatic athletes with CONTINUED T2-signal change and a spinal canal diameter >13 mm RTP should be taken on a case-by-case basis, but those with a canal diameter <13 mm should not RTP.	**Agree: 68.3 (41)** Disagree: 31.7 (19)	Super majority, weak consensus	92.3 (12/13) Strong consensus	.15
Following an injury, for asymptomatic athletes with no history of transient paralysis with CONTINUED T2-signal changes and a spinal canal diameter >13 mm RTP should be taken on a case-by-case basis, but those with canal diameters <13 mm should not RTP.	Agree: 49.3 (33) **Disagree: 50.7 (34)**	Simple majority, no consensus	38.5 (5/13) Weak consensus disagreement	.75

[a] A total of 17 physicians in the survey reported being affiliated with a professional collision/contact sports team.
[b] Fisher exact test comparing statement agreement between physicians affiliated and not affiliated with professional sports teams.
Bold highlights the response with the highest percentage.

with a professional team) disagreeing that RTP in asymptomatic athletes without evidence of cervical stenosis following a cervical spine injury and no history of transient paralysis but persistent MRI T2-signal changes should be approached on a case-by-case basis, but if there is any evidence of cervical stenosis, RTP should not be allowed (Table 2).

RTP Recommendations in Collision Sport Athletes After Cervical Spine Trauma and/or Surgery

For asymptomatic collision athletes after a cervical spine injury, 84.4% (strong consensus) of surgeons noted that solidly fused 1-/2-level ACDF patients could RTP when there are no MRI T2-signal changes; however, 3-level ACDF patients should not RTP, even without increased MRI changes. Similarly, athletes after a 1-level ACDF with continued MRI changes and a solid fusion (81.9%, strong consensus) or with pseudarthrosis (59.5%, simple majority without consensus) can RTP on a case-by-case basis, whereas multi-level ACDF patients should not RTP. Interestingly, 62.5% (weak consensus) of professional sports team-affiliated responders would consider RTP on a case-by-case basis for athletes with a 1-level ACDF and pseudarthrosis. For athletes with cervical spine fractures, 98.6% (strong consensus) would allow RTP as long as there is no instability or increased T2-signal changes. Remarkably, 100% of professional team-affiliated physicians would allow these patients to RTP. Finally, for athletes with solid fusion after a cervical spine fracture, RTP can be allowed if there are no MRI changes following a 1-/2-level ACDF or 1-level posterior cervical fusion (68.6%, weak consensus). Professional team-affiliated surgeons reached a strong consensus (75%) on this observation. Of note, for athletes with resolved transient paralysis and asymptomatic, 72.9% (strong consensus) of surgeons permitted RTP after a 1-/2-level ACDF if there were no T2-signal changes postoperatively, but case-by-case consideration was recommended after a corpectomy or posterior surgery (Table 3).

Third-round survey results for clarification of RTP in collision athletes after 2-level ACDF showed that the decision is controversial with only 50% (4/8) of responders allowing return to sport (Table 4).

Additional Considerations for RTP in Collision Sport Athletes

In terms of imaging in collision athletes after a cervical spine injury, 78.9% (strong consensus) of participants would obtain a screening MRI prior to participation clearance in athletes with a prior history of cervical spine pathology—excluding stingers. This same finding noted weak consensus among professional team-affiliated surgeons (69.2%). Moreover, for stingers, 69.9% (weak consensus) of surgeons would not obtain an MRI if symptoms resolved quickly after a first event, but any subsequent event would require MRI. Finally, RTP would be allowed by 84.5% (strong consensus) of participants if stinger symptoms resolved

Downloaded from https://academic.oup.com/neurosurgery/article/87/4/647/5876000 by Bora Laskin Law Library user on 30 November 2020

TABLE 3. RTP Guidelines After Cervical Trauma/Surgery

Statement	All physicians % (n)	Level of recommendation	% Agreement of professional sports team-affiliated physicians[a] % (n/responders)	*P* value[b]
RTP guidelines in collision athletes after cervical trauma and/or surgery				
Asymptomatic athletes with NO T2-signal change after a solid 1-/2-level ACDF are allowed to RTP, but a 3-level ACDF should not RTP.	**Agree: 84.4 (65)** Disagree: 15.6 (12)	Super majority, strong consensus	87.5 (14/16) Strong consensus	.52
Asymptomatic athletes with CONTINUED T2-signal change after a solid 2-/3-level ACDF should not RTP, but a 1-level ACDF should be taken on a case-by-case basis.	**Agree: 81.9 (59)** Disagree: 18.1 (13)	Super majority, strong consensus	86.7 (13/15) Strong consensus	.58
Athletes with pseudarthrosis following a 2-/3-level ACDF should not RTP, but pseudarthrosis of a 1-level ACDF should be taken on a case-by-case basis.	**Agree: 59.5 (44)** Disagree: 40.5 (30)	Simple majority, no consensus	62.5 (10/16) Weak consensus	.55
Asymptomatic athletes with a solid fusion after a compression fracture, burst fracture, or facet fracture with no instability and no T2-signal change are allowed to RTP.	**Agree: 98.6 (72)** Disagree: 1.4 (1)	Super majority, strong consensus	100 (16/16) Unanimous consensus	1.00
Asymptomatic athletes with a solid fusion after a cervical spine fracture and NO T2-signal change following a 1-/2-level ACDF or 1-level PCF are allowed to RTP.	**Agree: 68.6 (48)** Disagree: 31.4 (22)	Super majority, weak consensus	75 (12/16) Strong consensus	.54
Following an episode of transient paralysis, asymptomatic athletes with NO T2-signal change following a 1-/2-level ACDF are allowed to RTP, but following a corpectomy or posterior cervical surgery RTP should be taken on a case-by-case basis.	**Agree: 72.9 (43)** Disagree: 27.1 (16)	Super majority, strong consensus	64.3 (9/14) Weak consensus	.51

[a] A total of 17 physicians in the survey reported being affiliated with a professional collision/contact sports team.
[b] Fisher exact test comparing statement agreement between physicians affiliated and not affiliated with professional sports teams.
Bold highlights the response with the highest percentage.

within 5 min, but any episode lasting >5 min would require further evaluation (Table 5).

DISCUSSION

Universally accepted RTP recommendations in collision athletes after cervical spine injury have been difficult to develop. As recently as 2017, Nagoshi and colleagues[24] conducted a systematic review of RTP and cervical spine injuries. The authors noted a lack of high-level evidence throughout, with high risk of bias across the 16 studies meeting inclusion criteria. As a result, the report was unable to determine evidence-based RTP guidelines and resorted to expert opinion for controversial recommendations.[24] France and colleagues[34] in 2016 performed a survey of spine trauma surgeons treating cervical spine injuries to provide RTP recommendations based on a limited consensus expert opinion survey of spine trauma surgeons. Their study polled 25 surgeons from the Spine Trauma Study Group using 10 clinical scenarios of athletic cervical spine injuries, asking them to identify RTP recommendations after symptom recovery. Although the study did find consensus RTP in high-contact sports in the setting of cervical cord neuropraxia with full symptom resolution and no spinal canal stenosis, variability in clinical recommendations was observed in more complex scenarios with persistent symptoms, spinal canal stenosis or previous history of cervical fusion.[34] Moreover, the study was limited by the small number of experts surveyed, as well as the use of a simple survey methodology. Due to the lack of research on the topic and weak consensus achieved by previous studies, our team sought to develop improved guidelines. Our current consensus study was based on a proven process regularly used in the medical literature for developing and measuring consensus.[30]

RTP Recommendations in Collision Sport Athletes Based on Severity of Cervical Canal Stenosis

The presence of cervical spine stenosis has been a key factor considered in RTP decisions for collision sport athletes; however, the definition of cervical stenosis and how it relates to cervical spine injury has been a contentious topic.[25] The literature defines absolute cervical stenosis as an average cervical spine sagittal

Downloaded from https://academic.oup.com/neurosurgery/article/87/4/647/5876000 by Bora Laskin Law Library user on 30 November 2020

TABLE 4. Third-Round 1-/2-Level ACDF Clarification Survey

Question	All physicians % (n)	Level of recommendation
Third-round 2-level ACDF clarification survey		
Do you take care of American professional football players?	**Yes: 100.0 (8)** No: 0.0 (0)	N/A
Would you allow an asymptomatic player with full range of motion, no neurologic deficits, and no T2-signal changes on MRI, with a solid 1-level ACDF to return to play American football?	**Agree: 100.0 (8)** Disagree: 0.0 (0)	Unanimous, strongest consensus
Would you allow an asymptomatic player with full range of motion, no neurologic deficits, and no T2-signal changes on MRI, with a solid 2-level ACDF to return to play American football?	Agree: 50.0 (4) Disagree: 50.0 (4)	No consensus

RTP = return-to-play; MRI = magnetic resonance imaging; ACDF = anterior cervical discectomy and fusion.
Bold highlights the response with the highest percentage.

TABLE 5. Additional Consideration in RTP Guidelines

Statement	All physicians % (n)	Level of recommendation	% Agreement of professional sports team-affiliated physicians[a] % (n)	*P* value[b]
Additional considerations for RTP guidelines in collision athletes				
Athletes with prior nonoperative or operative treatment for cervical spinal pathology (with the exception of a stinger) should undergo a screening MRI prior to playing a competitive collision/contact sports.	**Agree: 78.9 (45)** Disagree: 21.1 (12)	Super majority, strong consensus	69.2 (9/13) Weak consensus	.45
Athletes who experience their first stinger with rapid resolution of symptoms do not require an MRI, however an MRI should be obtained after a second stinger.	**Agree: 69.9 (41)** Disagree: 30.5 (18)	Super majority, weak consensus	75 (9/12) Strong consensus	.50
Athletes who are asymptomatic for <5 min following a stinger are allowed to RTP, but for those with symptoms lasting >5 min RTP should be taken on a case-by-case basis.	**Agree: 84.5 (49)** Disagree: 15.5 (9)	Super majority, strong consensus	92.9 (13/14) Strong consensus	.41

[a]A total of 17 physicians in the survey reported being affiliated with a professional collision/contact sports team.
[b]Fisher exact test comparing statement agreement between physicians affiliated and not affiliated with professional sports teams.
Bold highlights the response with the highest percentage.

diameter <10 mm; whereas relative stenosis is defined as a canal diameter <13 mm.[21,35-37] Torg and colleagues developed the Torg-Pavlov ratio to evaluate the relationship between cervical spine stenosis and cervical spine injury. The measurement is defined as the ratio of the cervical canal diameter over the cervical vertebral body width, with a ratio of 0.8 or less indicating the presence of stenosis.[16,21,38] In addition, the implication of T2-signal hyperintensity changes on MRI after cervical spine injury in athletes is an important factor to consider in RTP decisions. T2 sequence changes generally indicate a traumatic event leading to edema and inflammation, with persistent or chronic signal changes linked to neurodegeneration and demyelination.[39-43] Tempel and colleagues[39] recently investigated these imaging changes, concluding that if athletes are asymptomatic with normal neurologic exams and no spine instability, RTP should not be contraindicated. Further, they noted that clearing an athlete for sports-related activity should not depend upon resolution of T2 hyperintensity changes. Based on these parameters and observations, once a collision sport athlete has experienced an episode of cervical spine injury in the form of transient paralysis or neuropraxia, the results of our consensus survey recommend that asymptomatic athletes without T2-signal changes on cervical MRI and without evidence of absolute cervical stenosis, or those with resolved T2-signal changes and without any evidence of cervical spine stenosis, are allowed to RTP. However, asymptomatic athletes with no MRI changes and with evidence of

Downloaded from https://academic.oup.com/neurosurgery/article/87/4/647/5876000 by Bora Laskin Law Library user on 30 November 2020

absolute cervical stenosis, those with resolved MRI changes and relative stenosis, or those with continued T2-signal changes and without evidence of any cervical stenosis, are allowed to RTP based on a case-by-case evaluation. Athletes with persistent T2-sequence changes and any form of cervical stenosis, or those with resolved MRI changes and absolute cervical stenosis, should not RTP. These recommendations have also been maintained by other recent guidelines, including Torg et al findings noting that cervical stenosis in stable spines do not predispose athletes to catastrophic injury and RTP should not be obstructed.[16,24,34,38] Nevertheless, clinical caution should always be exercised with close observation and counseling.

RTP Recommendations in Collision Sport Athletes After Cervical Spine Trauma and/or Surgery

Several previous studies reporting outcomes after cervical spine surgery in professional athletes exist, with most suggesting a majority of athletes will RTP within a year.[20,22,44-46] However, these studies are mostly limited to 1-level ACDFs, and data regarding 2 + fusion levels or posterior surgery is scant. Therefore, most clinicians note that decisions based on any guidelines should be made cautiously.[24,34,44] Nevertheless, our consensus study determined that asymptomatic athletes without T2-signal changes on MRI following a 1- or 2-level ACDF could be allowed to RTP; however, corpectomy or posterior cervical surgery RTP decisions should be made on a case-by-case basis, and 3-level ACDF athletes should not RTP. Interestingly, when considering only professional team-affiliated physicians, the observed overall strong consensus for 1-/2-level ACDF vs corpectomy/posterior surgery dropped to weak consensus (72.9% to 64.3%), reflecting the caution to fully endorse guidelines in high-level collision athletes without sufficient evidence available. Moreover, our panel agreed that 1-level ACDF athletes with continued T2-signal changes are not completely contraindicated to RTP, and that their status be evaluated on a case-by-case basis. This was not the case for 2 + level ACDF, where our panel agreed no RTP is indicated when T2-signal changes persist. As previously mentioned, multi-level fusions or surgical approaches other than ACDF tend to be controversial, and clinical decisions for RTP should be carefully addressed on a case-by-case basis.[16,18,22]

Previous reports have noted that although cervical fractures in collision athletes are rare, the inherent danger of the involved sports renders them difficult to consider in the setting of RTP, and they often carry the longest recovery times.[1,18,26] Like other guidelines, our panel agreed that athletes with healed fractures without instability or MRI changes should be allowed to RTP, even in the setting of surgical intervention with a 1-/2-level ACDF or 1-level PCF as long as there is solid fusion and no persistent MRI changes.[1,17,18,26,34] The literature does endorse that pain-free range of motion, evidence of stability on dynamic imaging, a normal neurologic exam, and healed fusions are necessary components of the RTP decision process.[1,17,18,22,26] Remarkably, there was unanimous consensus among participating professional team-affiliated physicians regarding RTP in athletes with a solid fusion for cervical spine fractures and no associated dynamic instability or persistent MRI changes.

Albeit consensus was reached regarding 1-/2-level ACDF in various scenarios, various responders voiced concern for 2-level ACDF cases in professional athletes. The third-round questionnaire was done in an attempt to appease these concerns utilizing an anonymous survey of 8 surgeons with confirmed involvement in the care of NFL athletes. The results corroborated the controversial nature of RTP decisions in these instances, as no consensus was reached regarding RTP after 2-level ACDF. Our results showed 50% of responders would not allow RTP even in solidly fused 2-level ACDF asymptomatic athletes with full range of motion and no neurologic deficits or MRI T2-signal changes. Given the risks of future injury and long-term consequences, any RTP decisions in this particular patient population need to be carefully considered jointly by the treating physician and the player on a case-by-case basis.[44]

Additional Considerations for RTP in Collision Sport Athletes

Previous studies have addressed the impact a past musculoskeletal medical history has on the career of professional-level football athletes.[47,48] Wang and colleagues studied NFL Scouting Combine participants, and determined that athletes with a history of cervical spine injury have significantly shorter careers and play in fewer games compared to controls.[48] Additionally, among NFL athletes, Schroeder et al determined that professional career outcomes depend on the type of cervical spine pathology an athlete may have, and concluded that each player with a history of cervical spine disease should have individualized evaluations to ensure productive and healthy NFL careers.[47] Supporting these observations, our panel agreed with strong consensus that athletes with a history of cervical spine pathology warrant a screening MRI prior to collision sports participation. Interestingly, professional sport affiliated participants also agreed with the statement, albeit with weak consensus.

For milder forms of cervical spine-associated neuropraxias, such as burners or stingers, timing of advanced imaging is debatable. Stingers are an episodic unilateral peripheral nervous system dysfunction, secondary to a compressive-type or traction-type nerve root or brachial plexus traumatic event.[1,25,26] Stingers are associated with dysesthesias, including burning, stinging, weakness and pain, and most episodes last minutes to hours before full symptom resolution [1,18,25,26] Almost all guidelines allow RTP as soon as symptoms revolve, and there is a documented normal neurologic examination with full active range of motion.[1,16,18,26] Most of these guidelines endorse advanced imaging after 3 or more stinger episodes or persistent symptoms, with RTP contraindicated until further work-up is performed to rule out a possible primary cervical spine abnormality.[1,16,18,25,26] Our current consensus agreed with advanced imaging requirements after a second stinger event, as long as the initial event had rapid symptom resolution. Furthermore, the panel agreed that symptomatic stingers for less than 5 min allow RTP for a collision

Downloaded from https://academic.oup.com/neurosurgery/article/87/4/647/5876000 by Bora Laskin Law Library user on 30 November 2020

athlete, whereas episodes lasting greater than 5 min warrant further consideration.

Limitations

This study was not without limitations. First, dependence on a panel of experts for clinical recommendations is suboptimal, yet in the absence of strong literature evidence, it is a suitable foundation for clinical practice recommendations. Second, another limitation of this study was the low rate of neurosurgeon participation. An attempt was made to include a breath of subspecialty participants during the 2019 CSRS annual meeting; however, not all participants identified their subspecialty field. Third, the survey process did not allow our team to account for all possible types of cervical spine injuries, surgeries or related considerations in collision athletes. Finally, even though we used a widely accepted process of consensus measurement, our results should not be interpreted as scientific fact, as they are only a measurement of expert opinion. This study does build upon previous guidelines and provide greater consensus strength given the modified Delphi process, as well as the larger number of participants.

CONCLUSION

While cervical spine injuries are rarely experienced by collision sport athletes, their long-term, life-altering effects warrant adequate clinical evaluation and effective nonoperative vs operative management. Though previous studies have provided limited RTP guidelines, the present study utilizes a systematic approach to establish greater consensus statement recommendations for the clinical RTP management of collision sport athletes with cervical spine injury. The results of this study provide clinical recommendations agreed upon by a large panel of leading spine surgeons. Notwithstanding, RTP after 2-level ACDF in this cohort of patients remains controversial. High-quality studies are likely to be impractical given the nature of the injury and situation; however, future studies are required to elucidate the most effective, up-to-date treatment plan and optimal timing for RTP following cervical spine injury.

Disclosures

The authors have no personal, financial, or institutional interest in any of the drugs, materials, or devices described in this article.

REFERENCES

1. Schroeder GD, Vaccaro AR. Cervical spine injuries in the athlete. *J Am Acad Orthop Surg*. 2016;24(9):e122-e133.
2. Hachem LD, Ahuja CS, Fehlings MG. Assessment and management of acute spinal cord injury: from point of injury to rehabilitation. *J Spinal Cord Med*. 2017;40(6):665-675.
3. Puvanesarajah V, Qureshi R, Cancienne JM, Hassanzadeh H. Traumatic sports-related cervical spine injuries. *Clin Spine Surg*. 2017;30(2):50-56.
4. Deckey DG, Makovicka JL, Chung AS, et al. Neck and cervical spine injuries in national college athletic association athletes. *Spine*. 2019;45(1):1.
5. Chung AS, Makovicka JL, Hassebrock JD, et al. Epidemiology of cervical injuries in NCAA football players. *Spine*. 2019;44(12):848-854.
6. Clarke KS. Epidemiology of athletic neck injury. *Clin Sports Med*. 1998;17(1):83-97.
7. U.S. Census Bureau. Table 1. Monthly Population Estimates for the United States, December 2019. www.census.gov. Accessed March 2020.
8. Woods RA. *The American Time Use Survey: Sports and Exercise*. Washington, DC: U.S. Bureau of Labor Statistics; 2017.
9. Lawrence DW, Hutchison MG, Comper P. Descriptive epidemiology of musculoskeletal injuries and concussions in the national football league, 2012-2014. *Orthop J Sports Med*. 2015;3(5):2325967115583653.
10. Mall NA, Buchowski J, Zebala L, Brophy RH, Wright RW, Matava MJ. Spine and axial skeleton injuries in the national football league. *Am J Sports Med*. 2012;40(8):1755-1761.
11. Kluczynski MA, Kelly WH, Lashomb WM, Bisson LJ. A systematic review of the orthopaedic literature involving national football league players. *Orthop J Sports Med*. 2019;7(8):2325967119864356.
12. Beaulieu-Jones BR, Rossy WH, Sanchez G, et al. Epidemiology of injuries identified at the NFL scouting combine and their impact on performance in the national football league: evaluation of 2203 athletes from 2009 to 2015. *Orthop J Sports Med*. 2017;5(7):232596711770874.
13. Tator CH, Provvidenza C, Cassidy JD. Spinal injuries in canadian ice hockey: an update to 2005. *Clin J Sport Med*. 2009;19(6):451-456.
14. Bailes JE, Hadley MN, Quigley MR, Sonntag VKH, Cerullo LJ. Management of athletic injuries of the cervical spine and spinal cord. *Neurosurgery*. 1991;29(4):491-497.
15. Cantu RC, Bailes JE, Wilberger JE. Guidelines for return to contact or collision sport after a cervical spine injury. *Clin Sports Med*. 1998;17(1):137-146.
16. Huang P, Anissipour A, McGee W, Lemak L. Return-to-Play recommendations after cervical, thoracic, and lumbar spine injuries. *Sports Heal*. 2016;8(1):19-25.
17. Vaccaro AR, Klein GR, Ciccoti M, et al. Return to play criteria for the athlete with cervical spine injuries resulting in stinger and transient quadriplegia/paresis. *Spine J*. 2002;2(5):351-356.
18. Torg JS. Cervical spine injuries and the return to football. *Sports Heal*. 2009;1(5):376-383.
19. Torg JS, Ramsey-Emrhein JA. Cervical spine and brachial plexus injuries. *Physician Sportsmed*. 1997;25(7):60-88.
20. McAnany SJ, Overley S, Andelman S, et al. Return to play in elite contact athletes after anterior cervical discectomy and fusion: a meta-analysis. *Global Spine J*. 2017;7(6):552-559.
21. Eddy D, Congeni J, Loud K. A review of spine injuries and return to play. *Clin J Sport Med*. 2005;15(6):453-458.
22. Kang DG, Anderson JC, Lehman RA. Return to play after cervical disc surgery. *Clin Sports Med*. 2016;35(4):529-543.
23. Cantu RC, Li YM, Abdulhamid M, Chin LS. Return to play after cervical spine injury in sports. *Curr Sports Med Rep*. 2013;12(1):14-17.
24. Nagoshi N, Tetreault L, Nakashima H, Nouri A, Fehlings MG. Return to play in athletes with spinal cord concussion: a systematic literature review. *Spine J*. 2017;17(2):291-302.
25. Rosenthal BD, Boody BS, Hsu WK. Return to play for athletes. *Neurosurg Clin N Am*. 2017;28(1):163-171.
26. Paulus S, Kennedy DJ. Return to play considerations for cervical spine injuries in athletes. *Phys Med Rehabil Clin North Am*. 2014;25(4):723-733.
27. Davis G, Ugokwe K, Roger EP, et al. Clinics in neurology and neurosurgery of sport: asymptomatic cervical canal stenosis and transient quadriparesis. *Br J Sports Med*. 2009;43(14):1154-1158.
28. Davis G, Hamlyn P, Sears WR, McCrory P. Clinics in neurology and neurosurgery of sport: cervical disc prolapse. *Br J Sports Med*. 2009;43(6):455-459.
29. Ukogu C, Bienstock D, Ferrer C, et al. Physician Decision-making in return to play after cervical spine injury: a descriptive analysis of survey data. *Clin Spine Surg*. published online: 2020 (doi:10.1097/bsd.0000000000000948).
30. Humphrey-Murto S, Wood TJ, Gonsalves C, Mascioli K, Varpio L. The delphi method. *Acad Med*. 2020;95(1):168.
31. Custer RL, Scarcella JA, Stewart BR. The modified delphi technique - A Rotational modification. *J Career Technical Educ*. 1999;15(2) (doi:10.21061/jcte.v15i2.702).
32. Robert HM. *Webster's New World Robert's Rules of Order Simplified and Applied*. 3rd ed. Boston: Houghton Mifflin Harcourt; 2014.
33. Peacock B. Laws & rules. *Ergonomics Des Q Hum Factors Appl*. 2006;14(1):4-34.
34. France JC, Karsy M, Harrop JS, Dailey AT. Return to play after cervical spine injuries: a consensus of opinion. *Global Spine J*. 2016;6(8):792-797.

Downloaded from https://academic.oup.com/neurosurgery/article/87/4/647/5876000 by Bora Laskin Law Library user on 30 November 2020

35. Prasad SS, O'Malley M, Caplan M, Shackleford IM, Pydisetty RK. MRI measurements of the cervical spine and their correlation to Pavlov's ratio. *Spine*. 2003;28(12):1263-1268.
36. Bajwa NS, Toy JO, Young EY, Ahn NU. Establishment of parameters for congenital stenosis of the cervical spine: an anatomic descriptive analysis of 1066 cadaveric specimens. *Eur Spine J*. 2012;21(12):2467-2474.
37. Jenkins TJ, Mai HT, Burgmeier RJ, Savage JW, Patel AA, Hsu WK. The triangle model of congenital cervical stenosis. *Spine*. 2016;41(5):E242-E247.
38. Torg JS, Naranja RJ, Pavlov H, Galinat BJ, Warren R, Stine RA. The relationship of developmental narrowing of the cervical spinal canal to reversible and irreversible injury of the cervical spinal cord in football players. An epidemiological study. *J Bone Jt Surg*. 1996;78(9):1308-1314.
39. Tempel ZJ, Bost JW, Norwig JA, Maroon JC. Significance of T2 hyperintensity on magnetic resonance imaging after cervical cord injury and return to play in professional athletes. *Neurosurgery*. 2015;77(1):23-31.
40. Song T, Chen W-J, Yang B, et al. Diffusion tensor imaging in the cervical spinal cord. *Eur Spine J*. 2011;20(3):422-428.
41. Sarkar S, Turel MK, Jacob KS, Chacko AG. The evolution of T2-weighted intramedullary signal changes following ventral decompressive surgery for cervical spondylotic myelopathy. *J Neurosurg Spine*. 2014;21(4):538-546.
42. Vedantam A, Rajshekhar V. Change in morphology of intramedullary T2-Weighted increased signal intensity after anterior decompressive surgery for cervical spondylotic myelopathy. *Spine*. 2014;39(18):1458-1462.
43. Collignon F, Martin D, Lénelle J, Stevenaert A. Acute traumatic central cord syndrome: magnetic resonance imaging and clinical observations. *J Neurosurg*. 2002;96(1 Suppl):29-33.
44. Watkins RG, Chang D, Watkins RG. Return to play after anterior cervical discectomy and fusion in professional athletes. *Orthop J Sports Med*. 2018; 6(6):232596711877967.
45. Meredith DS, Jones KJ, Barnes R, Rodeo SA, Cammisa FP, Warren RF. Operative and nonoperative treatment of cervical disc herniation in national football league athletes. *Am J Sports Med*. 2013;41(9):2054-2058.
46. Hsu WK. Outcomes following nonoperative and operative treatment for cervical disc herniations in national football league athletes. *Spine*. 2011;36(10):800-805.
47. Schroeder GD, Lynch TS, Gibbs DB, et al. The impact of a cervical spine diagnosis on the careers of national football league athletes. *Spine*. 2014;39(12):947-952.
48. Wang D, Weiss LJ, Abrams M, et al. Athletes with musculoskeletal injuries identified at the NFL scouting combine and prediction of outcomes in the NFL: a systematic review. *Orthop J Sports Med*. 2018;6(12):2325967118813083.

Supplemental digital content *is available for this article at www.neurosurgery-online.com.*

Supplemental Digital Content 1. Initial Questionnaire.
Supplemental Digital Content 2. Supplemental Tables.
Supplemental Table 1. RTP based on levels fused and MRI findings; RTP = return-to-play; MRI = magnetic resonance imaging; ACDF = Anterior Cervical Discectomy and Fusion.
Supplemental Table 2. RTP based on degree of stenosis adjacent to a solid fusion; RTP = return-to-play.
Supplemental Table 3. RTP based on levels fused and pseudarthrosis; RTP = return-to-play; ACDF = Anterior Cervical Discectomy and Fusion.
Supplemental Table 4. RTP Based on fracture type and instability; RTP = return-to-play.
Supplemental Table 5. RTP Based on surgical procedures; RTP = return-to-play; ACDF = Anterior Cervical Discectomy and Fusion.
Supplemental Table 6. RTP in an asymptomatic athlete without history of transient paralysis based on degree of stenosis and MRI findings; RTP = return-to-play; MRI = magnetic resonance imaging.
Supplemental Table 7. RTP in an asymptomatic athlete without history of transient paralysis based on MRI findings and surgical procedures; RTP = return-to-play; MRI = magnetic resonance imaging; ACDF = Anterior Cervical Discectomy and Fusion.
Supplemental Table 8. RTP in an asymptomatic athlete with history of transient paralysis based on degree of stenosis and MRI findings; RTP = return-to-play; MRI = magnetic resonance imaging.
Supplemental Table 9. RTP after an episode of transient paresis based on MRI Findings and surgical procedure; RTP = return-to-play; MRI = magnetic resonance imaging; ACDF = Anterior Cervical Discectomy and Fusion.
Supplemental Table 10. RTP After a Burner/Stinger Based on Symptoms; RTP = return-to-play; MRI = magnetic resonance imaging.
Supplemental Table 11. Recommendations for obtaining an MRI based on previous medical history; MRI = magnetic resonance imaging.

Downloaded from https://academic.oup.com/neurosurgery/article/87/4/647/5876000 by Bora Laskin Law Library user on 30 November 2020

Check for updates

[Orthopaedic Surgery]

CEU

Return-to-Play Recommendations After Cervical, Thoracic, and Lumbar Spine Injuries: A Comprehensive Review

Philip Huang, DO,*† Alireza Anissipour, DO,‡ William McGee, DO,§ and Lawrence Lemak, MD||

Context: Currently, there is a national focus on establishing and disseminating standardized guidelines for return to play for athletes at all levels of competition. As more data become available, protocols and guidelines are being refined and implemented to assist physicians, coaches, trainers, players, and parents in making decisions about return to play. To date, no standardized criteria for returning to play exist for injuries to the spine.

Evidence Acquisition: Electronic databases including PubMed and MEDLINE and professional orthopaedic, neurosurgical, and spine organizational websites were reviewed between 1980 and 2015.

Study Design: Clinical review.

Level of Evidence: Level 4.

Results: Although clinical guidelines have been published for return to play after spine injury, they are almost exclusively derived from expert opinion and clinical experience rather than from well-designed studies. Furthermore, recommendations differ and vary depending on anatomic location, type of sport, and surgery performed.

Conclusion: Despite a lack of consensus and specific recommendations, there is universal agreement that athletes should be pain free, completely neurologically intact, and have full strength and range of motion before returning to play after spinal injury.

Keywords: return to play; spine injury; sports; spine surgery

The annual incidence of spinal cord injury is approximately 40 cases per 1 million Americans, resulting in approximately 12,500 new cases each year.[32] After motor vehicle accidents (38%), falls (30%), and violence (14%), athletic participation accounts for 9% of these injuries. While spinal cord injuries resulting in death or permanent paralysis represent the most devastating spectrum of injury, cervical strains, burners, and stingers are far more common. Up to 70% of college football players experience burners or stingers during a 4-year career.[3] In the first 10 years after head-first tackling was banned in 1976, the rate of cervical injuries decreased by 70% at the high school level, from 7.72 per 100,000 to 2.31 per 100,000. Additionally, traumatic quadriplegia decreased by approximately 82% over the same 10-year period.[5,43] Significant advancements in personal protective equipment for contact athletes have contributed to the overall reduction in injury.[35,44]

Standardized protocols have been, or are currently being, developed for return to sport after anterior cruciate ligament (ACL) reconstruction, concussions, and many other musculoskeletal injuries treated both operatively and conservatively. However, there is no such consensus for return to play after injury to the spine in athletes. The reasons for the lack of guidelines are multifactorial but likely due to the more complex anatomy and wide spectrum of injuries to the spine, as well as the decreased incidence of these injuries over the past 40 years. The myriad spinal conditions, injuries, and surgical options highlight the need to evaluate return-to-play guidelines after spine injuries according to each specific injury and its

From †Midwestern University, Downers Grove, Illinois, ‡University of Washington, Seattle, Washington, §Total Sports Medicine Las Vegas, Las Vegas, Nevada, and ||Lemak Sports Medicine, Birmingham, Alabama

*Address correspondence to Philip Huang, DO, Midwestern University, Downers Grove, IL 60515 (email: philhuang1@gmail.com).

The following author declared potential conflicts of interest: Lawrence Lemak, MD, is a paid consultant for Drayer Physical Therapy and is Chief Medical Officer of Major League Soccer (MLS).

DOI: 10.1177/1941738115610753

© 2015 The Author(s)

respective treatment modality. The purposes of this article are to (1) review the available literature regarding return to play after spine injuries, including those treated surgically, and (2) provide a comprehensive review of current guidelines for return to play after injury to each anatomic location in the cervical, thoracic, and lumbar spine.

CERVICAL SPINE

Torg and Ramsey-Emrhein,[42] Cantu et al,[11] and Vaccaro et al[44] each proposed guidelines for the management of several major cervical spine injuries that included return-to-play recommendations. Torg and Ramsey-Emrhein[42] divided return-to-play criteria into 3 separate categories based on risk of serious injury or reinjury: (1) no contraindication with no increase in risk of serious injury, (2) absolute contraindication with a clear increased risk of serious injury, and (3) relative contraindications with no clear evidence of increased risk but possible recurrent injury or noncatastrophic injury (see Table 1 in Appendix, available at http://sph.sagepub.com/content/by/supplemental-data).[42] Cantu et al[11] also divided return-to-play criteria based on contraindications very similar to Torg's (see Table 2 in Appendix, available at http://sph.sagepub.com/content/by/supplemental-data). Perhaps the most comprehensive guidelines are those proposed by Vaccaro et al,[44] which also followed the works of Torg and discuss recommendations in similar terms (see Table 3 in Appendix, available at http://sph.sagepub.com/content/by/supplemental-data).

The 3 sets of guidelines are very similar, with some modifications made based on clinical experience and scientific data. The lack of consensus on the management of athletes after cervical spine injury has been highlighted.[31] Published guidelines were used in the decision for return to play in only 1 of 10 clinical scenarios.

Stingers and Burners

Stingers and burners are injuries to the cervical nerve roots that supply the upper extremities that result in transient loss in sensory and/or motor function that leads to stinging, burning, or radicular pain to the affected extremity.[29] Generally, symptoms are temporary and last a few seconds or minutes. These injuries can be acute or chronic but are typically the result of 1 of 3 mechanisms[35]: (1) stretch or traction of the brachial plexus from bending of the neck to the opposite side, usually as a result of tackling or landing on the side of the helmet; (2) hyperextension of the cervical spine resulting in nerve root compression in the neural foramina; or (3) direct blow to the brachial plexus at its most exposed anatomic location, which is defined as Erb's point. These injuries appear to be more consistent with the last mechanism—direct compression—due to the decrease in injuries in American football players at the United States Military Academy after using protective shoulder pads.[29]

Although the diagnosis of stingers/burners is usually evident from symptoms, it is important to consider more serious etiology as part of the differential diagnoses. These include fractures/dislocations of the cervical vertebrae, disk herniation, transient neurapraxia, and congenital abnormalities (Figure 1).[5]

There is some controversy regarding return to play after a stinger- or burner-type injury. More than 3 episodes of stingers/burners may be a relative contraindication for return to play.[11,45] There is consensus on return to play once the patient is completely symptom free and has full strength and range of motion without evidence of other injury on plain radiographs or advanced imaging. Players with a third stinger in the same season should undergo radiographs at a minimum.[27] For severe, persistent, or recurrent symptoms, magnetic resonance imaging (MRI), computed tomography (CT), and/or electromyography (EMG) are recommended to evaluate for congenital anomaly, stenosis, or further cord/nerve compromise.[11,45]

Cervical Strains and Sprains

Cervical soft tissue injuries generally include a ligamentous sprain or muscular strain in the supporting structures of the cervical spine. These players may return to competition once they meet the 4 general criteria already described.[40]

Of critical importance when evaluating the athlete with a suspected cervical strain is to rule out instability from complete ligamentous disruption. This can be particularly challenging in the young athlete, where ligamentous laxity is commonly seen as a normal variant.[8,11,49] A complete and thorough physical examination is of critical importance. In these cases, radiographs should not demonstrate any subluxation of the cervical vertebrae; flexion/extension views should be obtained initially as well as 2 to 4 weeks after the injury.[6,27] If instability is suspected based on symptoms or clinical examination, a hard cervical collar should be worn in the interim.[11]

Cervical Stenosis and Cervical Cord Neurapraxia

With cervical stenosis and cervical cord injury, evaluation of the Torg ratio and its relationship to injury of the cervical spinal cord has been recommended.[41] The Torg ratio is the distance from the midpoint of the posterior aspect of the vertebral body to the nearest point on the corresponding spinolaminar line and dividing this value by the anteroposterior diameter of the vertebral body measured on a lateral radiograph (Figure 2).[41] The normal Torg ratio is 1.0, with any value lower than 0.8 indicative of spinal stenosis.[41] Cervical cord neurapraxia may also present with transient quadriplegia/quadriparesis, which typically includes symptoms similar to central cord syndrome.[11] These symptoms manifest as temporary bilateral burning paresthesias and varying degrees of weakness involving the arms, legs, or all 4 extremities.[11,44] In a retrospective study, the Torg ratio was extremely sensitive: 93% for transient neurapraxia in football players.[41] However, the Torg ratio had a very low positive predictive value of 0.2% for determining future injury. Furthermore, the ratio may not be as accurate in professional football players due to their larger vertebral bodies that

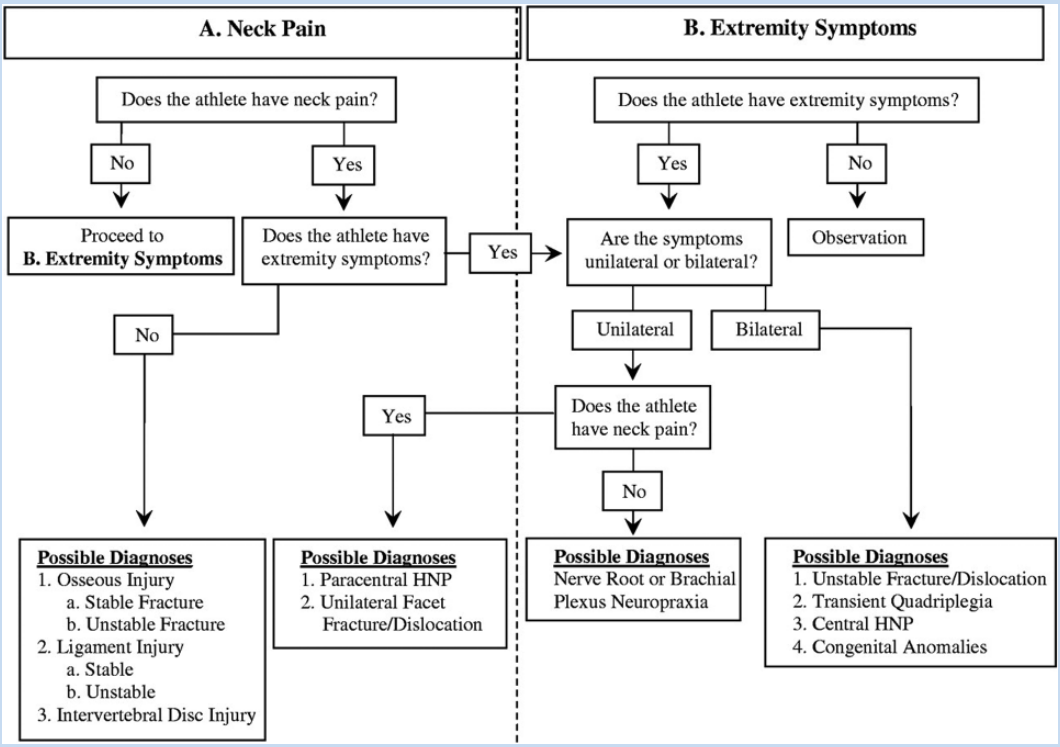

Figure 1. Diagnostic algorithm of cervical spine injuries. HNP, herniated nucleus pulposis. Reprinted with permission from Banerjee et al.[5]

inherently lower the ratio.[23] As such, it is not useful as a screening examination or to determine ability to return to play in contact sports.[41,44]

Alternatively, cervical stenosis may be evidenced by the amount of cerebrospinal fluid surrounding the cord.[11] "Functional" spinal stenosis is defined as a cervical spine canal so small that it obliterates the protective cushion of the cerebrospinal fluid (CSF) or, in extreme cases, may deform the spinal cord itself.[10] This should be an additional consideration in the evaluation of transient neurapraxia and return to play based on the premise that canal parameters measured on plain radiographs do not indicate functional stenosis.[11] Therefore, CT myelogram or MRI are needed to evaluate functional stenosis, which is a contraindication for return to play.[11]

The general recommendation for players who experience an episode of transient neurapraxia is plain radiographs and MRI.[27] If these studies do not reveal a cord abnormality, fracture, or neural compression and the player meets the 4 general criteria, they may return to play. However, with stenosis, ligamentous injury, cord defects, or edema, return to play is contraindicated.[27,40] There is some controversy regarding whether the above findings are absolute or relative contraindications.[11,44] The decision to return to play should be determined on an individual basis considering the degree of stenosis, the chance of reinjury dependent on sporting activity, and the severity of symptoms.

Cervical Disk Herniation

The prevalence of cervical disk herniation in the asymptomatic population is variable but may be 25% for those younger than 40 years and 60% for those older than 40 years.[20] There is a greater incidence of cervical disk disease in professional football players.[49] Asymptomatic disk herniation is not a contraindication to athletic participation.[27,42] As long as these athletes meet the general criteria, there may be no need for physical activity limitation.[8] However, symptomatic herniation is a contraindication for return to play.[27,42]

In all guidelines, symptomatic disk herniation remains an absolute contraindication to athletic participation.[11,18,42,45] The concern is that the relative spinal or foraminal stenosis caused by an acute disk herniation places the athlete at an increased risk for further and potentially more severe cord or nerve root damage.[27] Conservative management is the first-line treatment for acute cervical disk herniation.[49] Surgery should only be considered in the acute phase when myelopathy or progressive neurological deficits are present.[49] In American football players, excellent outcomes, higher return-to-play rates, and longer careers have been achieved surgically compared with conservative treatment.[24] This study only included players with

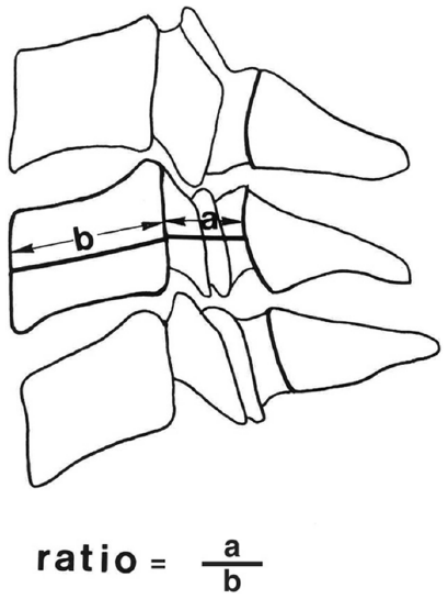

Figure 2. Torg ratio. "a" is the distance from the midpoint of the posterior aspect of the vertebral body to the nearest point on the corresponding spinolaminar line and "b" is the anteroposterior diameter of the vertebral body. Ratio is obtained by dividing "a" by "b."

a single cervical-level fusion. Controversy remains about management and return-to-play guidelines for athletes with multiple fusion levels.[11,44] Two-level fusions are considered a relative contraindication, even with a well-healed fusion in players who meet the general criteria.[42,45]

No consensus exists regarding return-to-play recommendations after injury to the cervical spine. An individualized approach to each athlete is recommended that includes careful consideration of the mechanism of injury, the anatomy of the patient, the anatomic location of the injury, plain radiographs and advanced imaging, and the patient's recovery. The athlete should have, at a minimum, a full and pain-free range of motion with full strength and no neurologic findings before returning to play.

THORACIC SPINE

In contrast to the cervical and lumbar spine, there are no published guidelines for return to play after injuries to the thoracic region. These injuries are much less common due to the biomechanics of the thoracic spine, its relative immobility compared with the cervical and lumbar regions, and the protection afforded by the rib cage.[9] Spinal stenosis is less likely to occur in this region due to the larger ratio of spinal cord to spinal canal diameter.[9]

Compression fractures, though common in the general aging population, are relatively rare in young athletes. According to the American Association of Neurosurgeons, approximately 750,000 vertebral compression fractures are diagnosed each year, mostly in postmenopausal women older than 80 years.[4] There are no such statistics for professional athletes, and only a few scattered case reports exist in the literature. Compression fractures of the eighth and ninth thoracic vertebrae in a professional football player have been managed conservatively with a thoracolumbar spinal orthosis, with athletic participation after 3 months and a return after 2 years to professional football without limitation or pain.[17] A T12 compression fracture in an 18-year-old basketball player was treated conservatively, and the patient returned to play after 3 months.[30] Similar treatment has returned patients to contact sports after healed compression fractures in the thoracic spine if the patient meets general criteria.[30] A similar conservative treatment approach and return-to-play criteria have been suggested for spinous process and transverse process fractures.[16]

Acute fractures of the spine with instability of the spinal column (burst or Chance fractures) are contraindications to athletic participation.[16] After surgical stabilization, however, there are a few proposed return-to-play guidelines.[17,30] Spinal fusions that bypass transition zones in the cervicothoracic or thoracolumbar region are an absolute contraindication to participation in contact sports.[9] Similarly, fusions that terminate at these transition zones represent a contraindication for return to play.[9] However, players may return to play if a fusion does not cross transitional levels and they meet general criteria.[9]

LUMBAR SPINE

Two recent guidelines have been proposed for managing the following injuries to the lumbar spine: strain, herniated disk, lumbar stenosis, spondylolysis, and spondylolisthesis (see Table 4 in Appendix, available at http://sph.sagepub.com/content/by/supplemental-data).[15,16]

Lumbar Strain

Strains in the lumbar region are among the most commonly encountered injuries and are responsible for 70% of low back pain in the general population.[13,15] Radiographs or advanced imaging are warranted in athletes with persistent pain, neurologic symptoms, radicular type pain, or a clinical suspicion for more serious etiology. Management of these injuries is conservative and consists of rest, ice, anti-inflammatory medications, and progressive return to activity as tolerated by the athlete.[21] Pain should be used as a guide for advancing activity levels, and the general criteria should be met before returning to competition.[15]

Herniated Nucleus Pulposis

Lumbar disk herniation is more prevalent in elite athletes compared with the general population, especially in gymnasts and American football linemen.[28,48] Plain radiographs are of limited value in the evaluation of disk disease, and MRI is considered the gold standard. However, MRI findings should correlate with the athlete's symptoms and examination, as

herniated disks and degenerative changes are commonly seen in up to 35% of asymptomatic patients aged 20 to 39 years.[26] Herniation in athletes is often the result of the rigorous demands of weight training and performance. The body mass index (BMI) of some professional athletes, the repetitive and strenuous motions of tackling, and repeated lumbar flexion/hyperextension are also contributing factors (eg, gymnasts, football linemen).[48]

Most athletes respond well to conservative management, including epidural steroid injections.[16] Failed conservative management, cauda equina syndrome, or progressive, profound neurological deficit represent indications for surgical intervention. The SPORT (Spine Patient Outcomes Research Trial) studies illustrate excellent outcomes of surgical treatment of lumbar disk herniation in the general population[47] but may not be applicable to the professional athlete.

The Professional Athlete Spine Initiative demonstrated a very high return-to-play rate (81%) after surgical treatment of herniated lumbar disks,[25] as have other studies in professional athletes.[48] The notable differences in these outcomes and return-to-play rates are dependent on the age of the player at the time of surgery and the type of sport.[25] A case series of professional athletes undergoing lumbar discectomy found return-to-play rates stratified according to a time line.[46] The rates of return were 50% at 3 months, 72% at 6 months, 79% at 9 months, and 84% at 12 months; the overall rate of return was 89%. The mean time to return to play was 5.3 months.[46]

With conservative management, the athlete should meet general return-to-play criteria before resuming activity. Return to play after 2 to 6 months is plausible for contact sports after percutaneous discectomy and microdiscectomy (see Table 4 in Appendix) and 4 to 8 weeks for lighter activities such as golf.[1]

Spondylolysis

Spondylolysis has an estimated prevalence of approximately 3% to 6% in the general population, although this is higher in athletes.[38] The most common locations for this injury are at L5 in 85% to 95% of cases and L4 in 5% to 15% of cases.[12,19,36] Spondylolysis is more commonly encountered in the skeletally immature athlete due to the vulnerability of the immature pars to repeated stress.[16] These patients typically respond well to nonoperative management, with bracing and activity modification when compared with their skeletally mature counterparts.[16,39] Patients typically present with localized lumbar pain that is worsened with extension. There should be a high index of suspicion in the skeletally immature athlete with these symptoms. Sports with repetitive stresses to the lumbar spine such as gymnastics, diving, weightlifting, and wrestling demonstrate the highest risk.[12,19,36] Initial evaluation should include anterior-posterior and lateral radiographs. The diagnostic benefit of additional oblique films is currently controversial.[7] Single photon emission computed tomography (SPECT) is helpful when initial screening radiographs are negative.[16]

Initial treatment includes bracing and activity modification, followed by progressive physical therapy.[16] Good to excellent results have been reported in 80% of athletes with spondylolysis treated conservatively.[14] These athletes are allowed to return to play once they have met the general criteria for contact sports, usually a minimum of 4 to 6 weeks.[16] Longer periods of rest and immobilization (8-12 weeks) have also been advocated.[33] Regardless, for athletes who fail conservative management, surgical treatment with iliac crest bone grafting and posterolateral fusion have been recommended.[22,38]

Return to play after surgical treatment of spondylolysis is controversial, and formal criteria are lacking. Guidelines do not recommend return to contact sports after fusion of spondylolysis.[15,16] A survey of 261 Scoliosis Research Society (SRS) members found that 27% to 36% of surgeons allowed these patients to return to collision sports 1 year postoperatively.[37] Fusion after spondylolysis is not always a contraindication to return to contact sports, but the time frame for return is variable.[9]

Spondylolisthesis

An isthmic spondylolisthesis is the result of bilateral pars fractures or defects that result in anterior slippage of the vertebral body.[39] Radicular pain and weakness may be present from foraminal or central stenosis depending on the severity of the slip. As with spondylolysis, the majority of low-grade spondylolistheses are treated conservatively, though bracing is more controversial.[15] Surgery is typically reserved for traumatic cases, higher grade (III-IV) slips, and failed conservative management.[15,16,33,39]

Specific return-to-play recommendations vary among spine surgeons[34] but generally include a pain-free full range of motion, the absence of neurological deficit, and evidence of bony fusion on plain radiographs.[9,15,16,33] Good outcomes have been reported in patients undergoing posterolateral fusion for spondylolysis and spondylolisthesis.[28] Return to sport is feasible after direct pars repair, which preserves spinal motion[28] in athletes with these conditions.[13,34] Direct pars repair may be advantageous in the athletic population.

Lumbar Stenosis

In young athletes, lumbar stenosis usually results from structural deformities such as spondylolisthesis, kyphosis, scoliosis, or disc herniation. Pain is worse with activity and better with lumbar flexion. Radicular pain and decreased strength and sensation may also be present. Unless the athlete has cauda equina syndrome, profound neurological deficit, or instability, the initial treatment is conservative.[15] Rest from activity, nonsteroidal anti-inflammatory medications, and progressive therapy with return to play are included in most conservative protocols.[2,15] Studies are not available on surgical treatment of spinal stenosis in athletes.[28]

Return-to-play guidelines for lumbar stenosis after surgical intervention are variable and highly dependent on the type of surgery performed (see Table 4 in Appendix). Athletes

may resume noncontact activity once they meet general criteria.[15] As stated earlier, athletes have returned to play with excellent outcomes after lumbar discectomy for disc herniation.[25,48] However, contact or collision sports are not advised after lumbar fusion for herniation or stenosis.[28] After laminectomy, the time frame for return to contact sports is usually 4 to 6 months.[1,15] Persistent neurological deficits, spinal instability, and postfusion procedures prohibit participation in collision sports.[2] Lumbar fusion alone or with interbody techniques may not be a contraindication to returning to contact sports after a complete recovery.[9]

CONCLUSION

Currently, there are no standardized consensus guidelines for return to play after spine injuries. However, there is good general agreement on 4 fundamental criteria that must be met for a player to return to playing a sport; the athlete should be pain free, have full range of motion, full strength, and no evidence of neurologic injury.

Clinical Recommendations

SORT: Strength of Recommendation Taxonomy
A: consistent, good-quality patient-oriented evidence
B: inconsistent or limited-quality patient-oriented evidence
C: consensus, disease-oriented evidence, usual practice, expert opinion, or case series

Clinical Recommendation	SORT Evidence Rating
Return-to-play recommendations after spine injuries are widely variable, but at a minimum, general criterion should be met prior to resuming athletic participation. These criteria include the following: full strength, painless and full range of motion, and full strength without neurologic deficit.[9,11,16]	C
Absolute contraindications to return to play for contact sports include but are not limited to: atlanto-occipital fusion, evidence of bony or ligamentous instability, symptomatic disc herniation, neurologic deficit, myelopathy, Arnold-Chiari malformation, and multilevel (2-3) spinal fusions.[11,42,44]	C
There is a lack of consensus regarding specific return-to-play criteria after spine surgery and injury.[16,28]	C

REFERENCES

1. Abla AA, Maroon JC, Lochhead R, Sonntag VK, Maroon A, Field M. Return to golf after spine surgery. *J Neurosurg Spine*. 2011;14:23-30.
2. Alsobrook J, Clugston JR. Return to play after surgery of the lumbar spine. *Curr Sports Med Rep*. 2008;7:45-48.
3. American Academy of Orthopedic Surgeons. OrthoInfo—Burners and Stingers 2014. http://orthoinfo.aaos.org/topic.cfm?topic=A00027. Accessed March 20, 2015.
4. American Association of Neurological Surgeons. Vertebral Compression Fractures-Patient Information 2014. http://www.aans.org/patient%20information/conditions%20and%20treatments/vertebral%20compression%20fractures.aspx. Accessed March 10, 2015.
5. Banerjee R, Fadale P, Palumbi M. Cervical spine injuries in the athlete. In: Johnson DH, Pedowitz RA, eds. *Practical Orthopedic Sports Medicine and Arthroscopy*. Philadelphia, PA: Lippincott Williams & Wilkins; 2007:54-69.
6. Banerjee R, Palumbo MA, Fadale PD. Catastrophic cervical spine injuries in the collision sport athlete. Part I. Epidemiology, functional anatomy, and diagnosis. *Am J Sports Med*. 2004;32:1077-1087.
7. Beck NA, Miller R, Baldwin K, et al. Do oblique radiographs add value in the diagnosis of spondylolysis in adolescents? *J Bone Joint Surg Am*. 2013;95:e65.
8. Brigham CD, Capo J. Cervical spinal cord contusion in professional athletes: a case series with implications for return to play. *Spine (Phila Pa 1976)*. 2013;38:315-323.
9. Burnett MG, Sonntag VK. Return to contact sports after spinal surgery. *Neurosurg Focus*. 2006;21:E5.
10. Cantu RC. Functional cervical spinal stenosis: a contraindication to participation in contact sports. *Med Sci Sports Exerc*. 1993;25:316-317.
11. Cantu RC, Li YM, Abdulhamid M, Chin LS. Return to play after cervical spine injury in sports. *Curr Sports Med Rep*. 2013;12:14-17.
12. Ciullo JV, Jackson DJ. Pars interarticularis stress reaction, spondylolysis, and spondylolisthesis in gymnasts. *Clin J Sports Med*. 1985;4:95-110.
13. Debnath UK, Freeman BJ, Gregory P, de la Harpe D, Kerslake RW, Webb JK. Clinical outcome and return to sport after the surgical treatment of spondylolysis in young athletes. *J Bone Joint Surg Br*. 2003;85:244-249.
14. d'Hemecourt PA, Zurakowski D, Kriemler S, Micheli LJ. Spondylolysis: returning the athlete to sports participation with brace treatment. *Orthopedics*. 2002;25:653-657.
15. Eck JC, Riley LH 3rd. Return to play after lumbar spine conditions and surgeries. *Clin J Sports Med*. 2004;23:367-379.
16. Eddy D, Congeni J, Loud K. A review of spine injuries and return to play. *Clin J Sport Med*. 2005;15:453-458.
17. Elattrache N, Fadale P, Fu F. Thoracic spine fracture in a football player. *Am J Sports Med*. 1993;21:157-160.
18. Ellis JL, Gottlieb JE. Return-to-play decisions after cervical spine injuries. *Curr Sports Med Rep*. 2007;6:56-61.
19. Fredrickson BE, Baker D, McHolick WJ, Yuan HA, Lubicky JP. The natural history of spondylolysis and spondylolisthesis. *J Bone Joint Surg Am*. 1984;66:699-707.
20. Furman MB, Puttlitz KM, Falco FJE, Simon J, Tekmyster G. Cervical disc disease. *eMedicine. Medscape*. http://emedicine.medscape.com/article/305720-overview. Accessed March 10, 2015.
21. Haus BM, Micheli LJ. Back pain in the pediatric and adolescent athlete. *Clin J Sports Med*. 2012;31:423-440.
22. Helenius I, Lamberg T, Osterman K, et al. Scoliosis research society outcome instrument in evaluation of long-term surgical results in spondylolysis and low-grade isthmic spondylolisthesis in young patients. *Spine (Phila Pa 1976)*. 2005;30:336-341.
23. Herzog RJ, Wiens JJ, Dillingham MF, Sontag MJ. Normal cervical spine mophometry and cervical spinal stenosis asymptomatic professional football players. *Spine (Phila Pa 1976)*. 1991;16(6 suppl):S178-S186.

24. Hsu WK. Outcomes following nonoperative and operative treatment for cervical disc herniations in National Football League athletes. *Spine (Phila Pa 1976)*. 2011;36:800-805.
25. Hsu WK, McCarthy KJ, Savage JW, et al. The professional athlete spine initiative: outcomes after lumbar disc herniation in 342 elite professional athletes. *Spine J*. 2011;11:180-186.
26. Jensen MC, Brant-Zawadski MN, Obuchowski N. Magnetic resonance imaging of the lumbar spine in people without back pain. *N Engl J Med*. 1994;331:69-73.
27. Kepler CK, Vaccaro AR. Injuries and abnormalities of the cervical spine and return to play criteria. *Clin J Sports Med*. 2012;31:499-508.
28. Li Y, Hresko MT. Lumbar spine surgery in athletes: outcomes and return-to-play criteria. *Clin J Sports Med*. 2012;31:487-498.
29. Markey K, DiBenedetto M, Curl W. Upper trunk brachial plexopathy: the stinger syndrome. *Am J Sports Med*. 1993;21:650-655.
30. McHugh-Pierina VL, Zillmer DA, Giangarra CE. Thoracic compression fracture in a basketball player. *J Athl Train*. 1995;30:163-164.
31. Morganti C, Sweeney CA, Albanese SA, Burak C, Hosea T, Connolly PJ. Return to play after cervical spine injury. *Spine (Phila Pa 1976)*. 2001;26:1131-1136.
32. National Spinal Cord Injury Statistical Center (NSCISC). *Spinal Cord Information Network—Facts and Figures at a Glance*. Birmingham, AL: University of Alabama at Birmingham; 2014.
33. Radcliff KE, Kalantar SB, Reitman CA. Surgical management of spondylolysis and spondylolisthesis in athletes: indications and return to play. *Curr Sports Med Rep*. 2009;8:35-40.
34. Reitman CA, Esses SI. Direct repair of spondylolytic defects in young competitive athletes. *Spine J*. 2002;2:142-144.
35. Rihn JA, Anderson DT, Lamb K, et al. Cervical spine injuries in American football. *Sports Med*. 2009;39:697-708.
36. Rossi F, Dragoni S. Lumbar spondylolysis: occurrence in competitive athletes: updated achievements in a series of 390 cases. *J Sports Med Phys Fitness*. 1990;30:450-452.
37. Rubery PT, Bradford DS. Athletic activity after spine surgery in children and adolescents: results of a survey. *Spine (Phila Pa 1976)*. 2002;27: 423-427.
38. Sutton JH, Guin PD, Theiss SM. Acute lumbar spondylolysis in intercollegiate athletes. *J Spinal Disord Tech*. 2012;25:422-425.
39. Tallarico RA, Madom IA, Palumbo MA. Spondylolysis and spondylolisthesis in the athlete. *Am J Sports Med*. 2000;28:57-62.
40. Torg JS. Cervical spine injuries and the return to football. *Sports Health*. 2009;1:76-383.
41. Torg JS, Naranja RJ, Pavlov H. The relationship of developmental narrowing of the cervical spinal canal to reversible and irreversible injury of the cervical spinal cord in football players. *J Bone Joint Am*. 1996;78-A:1308-1314.
42. Torg JS, Ramsey-Emrhein JA. Cervical spine and brachial plexus injuries: return-to-play recommendations. *Phys Sportsmed*. 1997;25:61-88.
43. Torg JS, Vegso JJ, O'Neill MJ, Sennett B. The epidemiologic, pathologic, biomechanical, and cinematographic analysis of football-induced cervical spine trauma. *Am J Sports Med*. 1990;18:50-57.
44. Vaccaro AR, Klein GR, Ciccoti M, et al. Return to play criteria for the athlete with cervical spine injuries resulting in stinger and transient quadriplegia/paresis. *Spine J*. 2002;2:351-356.
45. Vaccaro AR, Watkins B, Albert TJ, Pfaff WL, Klein GR, Silber JS. Cervical spine injuries in athletes: current return-to-play criteria. *Orthopedics*. 2001;24:699-703.
46. Watkins RG 4th, Hanna R, Chang D, Watkins RG 3rd. Return-to-play outcomes after microscopic lumbar diskectomy in professional athletes. *Am J Sports Med*. 2012;40:2530-2535.
47. Weinstein J, Lurie JD, Tosteson TD, et al. Surgical vs nonoperative treatment for lumbar disc herniation: the spine patient outcomes research trial: a randomized trial. *JAMA*. 2006;296:2451-2459.
48. Weistroffer JK, Hsu WK. Return-to-play rates in National Football League linemen after treatment for lumbar disk herniation. *Am J Sports Med*. 2011;39: 632-636.
49. Zmurko MG, Tannoury TY, Tannoury CA, Anderson DG. Cervical sprains, disc herniations, minor fractures, and other cervical injuries in the athlete. *Clin J Sports Med*. 2003;22:513-521.

For reprints and permission queries, please visit SAGE's Web site at http://www.sagepub.com/journalsPermissions.nav.