

Evaluation & Management of Penetrating Wounds to the Abdomen, Flank and Back

Goal

- Identify patients with a high probability of requiring surgical intervention
- Minimize unnecessary surgery
- Identify patients who might be discharged home directly from the ED

Guidelines:

I. Indications for Immediate Laparotomy:

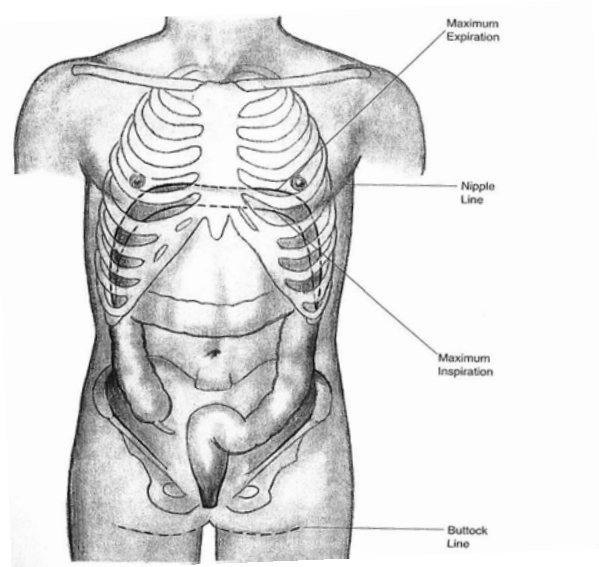
- **Transabdominal GSW – ALL** regardless of hemodynamic status
 - * Consider laparoscopy or CT in cases where the trajectory of the bullet may be tangential in order to confidently exclude peritoneal violation.
 - * Careful physical exam to ensure all wounds are accounted for
 - * Plain films to ensure all possible missiles are accounted for.
- **Stab Wounds with hemodynamic instability** defined as:
 - * Persistent/ transient hypotension (SBP<90)
 - * **OR** Significant tachycardia that in the opinion of the surgeon is due to blood loss
 - * **OR** Shock as evidenced by a significant base deficit (>6) on ABG
- **Flank or Back GSW with hemodynamic instability** (as above) **or peritonitis.**
- **Wounding instrument in situ**
- **Omental or intestinal evisceration**
- **Peritonitis**
- **Upper or lower GI bleeding**
- **Evidence of diaphragmatic injury (NG tube in chest, enteric contents through chest tube)**

PITFALLS: Hemodynamically abnormal patients should have an AP CXR to rule out hemo/pneumothorax as the cause of hypotension. Upper quadrant, epigastric or posterior chest wounds require a FAST to rule out pericardial fluid.

This serves as guideline only. Individual circumstances can vary and clinical judgment should always be used. When in doubt, consult with the Trauma Attending On-Call.

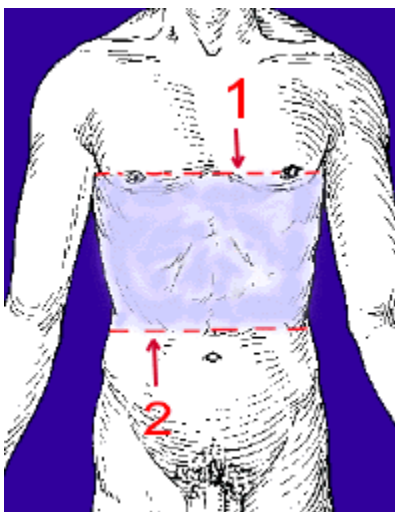
Boundaries

These guidelines cover from the nipples to groin anteriorly and from the inferior border of the scapula to the inferior gluteal fold posteriorly. Note how the abdomen extends almost to the nipples at maximal inspiration.



Thoracoabdominal region

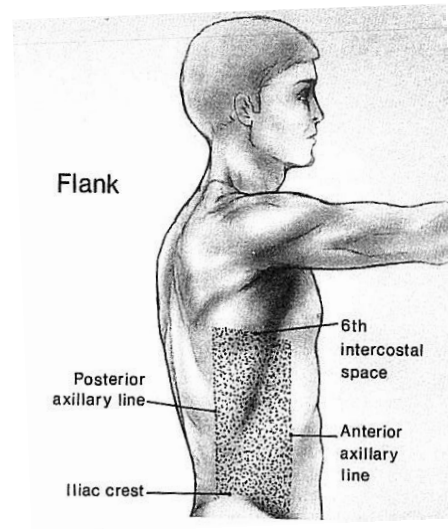
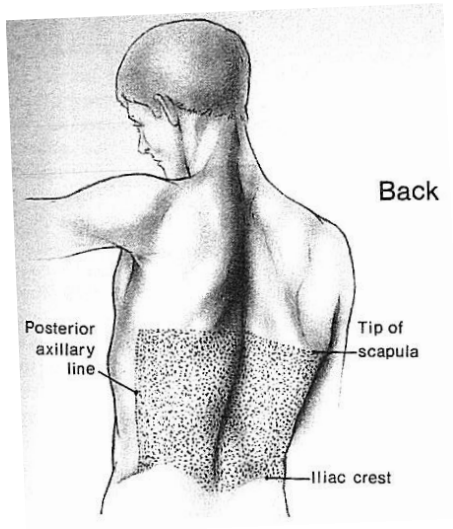
This region is of importance because of the challenges in evaluating the diaphragm. Boundaries extend from the nipples (males) or inframammary fold (females) to the costal margin and extend circumferentially to the back for 360 degrees.



This serves as guideline only. Individual circumstances can vary and clinical judgment should always be used. When in doubt, consult with the Trauma Attending On-Call.

Back and flank

The evaluation of the stable patient with back and flank stab wounds differs slightly due to the thick musculature in this region and the potential for injury to retroperitoneal structures



II. Anterior Abdominal Stab Wound Management – Hemodynamically Normal

Upper quadrant or epigastric wounds require a FAST to rule out pericardial fluid. After this, there are several options for the evaluation of hemodynamically normal patients with anterior abdominal stab wounds:

1. Observation
 - a. Observation with serial abdominal exams, serial CBC (q4h), VS q2h then discharge. Discharge appears to be safe after 12 hours of observation. Any change in the physical exam, increasing pain, or a drop in HgB should lead to consideration for laparotomy
 - b. Pros and cons
 - Pros:** Simple, low risk to patient, no radiation exposure
 - Cons:** Occupies a bed (in ED or ward), potential late recognition of an injury requiring operative intervention if patient not closely watched. Delays in recognition might occur for epigastric, particularly right upper quadrant wounds where bile peritonitis (e.g. gallbladder injury) might not manifest early
2. Local Wound Exploration (LWE)
 - a. Best for thin, cooperative patients
 - b. LWE is performed by prepping and draping the wound, then infiltrating the wound with local anesthetic. Extend the wound as required and using an assistant with retractors; (if necessary) follow the trajectory to determine if the wound penetrates the fascia (and ideally the peritoneum). If you are certain it does not, the patient can be discharged home from the ED without a period of observation. If it does, you must either observe the patient for 12 hours (as above) or do a CT scan to determine whether there is an indication for immediate operation.
 - c. Pros and cons
 - Pros:** Can lead to relatively quick discharge from the ED, no radiation exposure
 - Cons:** Takes some time, difficult to do in uncooperative, obese patients or if the wound takes an oblique course. Sometimes it's difficult to assess end of tract.
3. CT abdomen
 - a. Best for multiple stab wounds, obese patients
 - b. CT with IV contrast can be used to evaluate whether peritoneal penetration has taken place. If there is certainty that there is no peritoneal penetration, the patient can be discharged home following the CT scan. If peritoneal penetration has taken place but there is no suggestion of injury to a hollow viscus (stomach, small bowel, colon), then the patient will need to be observed for 12 hours prior to discharge. If peritoneal penetration has occurred and there is a suggestion of bowel injury (free fluid, bowel wall thickening), then laparotomy should be considered.

This serves as guideline only. Individual circumstances can vary and clinical judgment should always be used. When in doubt, consult with the Trauma Attending On-Call.

- c. If there is evidence of solid organ injury alone (liver/spleen) then depending on trajectory, potential for other injuries, and extent of hemoperitoneum, either operation or observation in a monitored setting (i.e. step down unit, ICU) are appropriate.
 - d. Pros and cons
 - Pros:** Good for assessment in obese patients, those where an isolated solid organ injury is likely, multiple wounds, or oblique wound tracts
 - Cons:** Radiation exposure, excluding peritoneal violation with certainty might not be possible, might not be possible to differentiate peritoneal penetration alone from peritoneal penetration with hollow viscus injury
4. Laparoscopy
- a. Best if other tests cannot rule out peritoneal violation or for assessment of the diaphragm
 - b. Laparoscopy in most hands is not ideal for excluding bowel injury, so if peritoneal penetration is demonstrated, conversion to laparotomy should be considered.
 - c. Pros and cons
 - Pros:** Best test short of laparotomy for excluding peritoneal violation. Short post-op LOS compared to laparotomy
 - Cons:** Consumes OR resources, time consuming, LOS no shorter than 12-hr period of observation

III. Back or Flank Stab Wound

Local wound exploration is usually not appropriate for wounds to the back or flank as the thickness of the musculature prevents a good assessment of trajectory.

Options for evaluation include:

1. Observation with serial abdominal exams, serial CBC (q4h), VS q2h then discharge. Discharge appears to be safe after 12 hours of observation. Any change in the physical exam, increasing pain, or a drop in HgB should lead to consideration for laparotomy
2. Triple contrast CT scan
 - a. Best to exclude injuries requiring management and to evaluate hematuria
 - b. Requires oral, IV and rectal contrast. If the injury is on the right side, then a thorough evaluation requires that oral contrast enter the duodenum and rectal contrast enters the right colon. If CT is negative (no retroperitoneal or peritoneal violation), the patient may be discharged home. If equivocal for (retro)peritoneal violation, admit patient for observation. If there is violation of the peritoneum or retroperitoneum but there is no suggestion of injury to a hollow viscus (stomach, duodenum, small bowel, colon), then the patient will need to be observed for 12 hours prior to discharge. If violation penetration has occurred and there is a suggestion of bowel injury (free fluid, bowel wall thickening), then laparotomy should be considered.

This serves as guideline only. Individual circumstances can vary and clinical judgment should always be used. When in doubt, consult with the Trauma Attending On-Call.

- c. If there is an injury to the kidney or hematuria is present, then delayed CT cuts (10 min) of the kidneys, ureter and bladder should be obtained to evaluate the collecting system and ureter.
- d. If there is evidence of solid organ injury alone (liver/spleen) then depending on trajectory, potential for other injuries, and extent of hemoperitoneum, either operation or observation in a monitored setting (i.e. step down unit, ICU) are appropriate.

IV. Thoracoabdominal Stab Wounds

Evaluation of these wounds requires consideration of potential injury to the diaphragm. Imaging modalities lack sensitivity in picking up injuries to the diaphragm. It is believed that missing a small right sided diaphragmatic injury has limited, if any long term consequence. The fate of small left-sided diaphragmatic injuries is less clear, with many believing these will go on to larger diaphragmatic hernias if unrepaired.

1. Evaluation should begin with an **upright** CXR along with a pericardial and abdominal FAST. A hemo/pneumothorax will require a chest tube. At the time of chest tube insertion, the diaphragm might be assessable using digital assessment. Indications for laparotomy at this time would include any of the findings below:
 - a. A palpable tear/rent in the diaphragm at the time of chest tube insertion.
 - b. A positive FAST
 - c. Enteric contents from the chest tube

Note a diaphragm injury following thoracoabdominal stab wounds have a 25-50% rate of associated hollow viscus injuries, hence the need to approach them from the abdomen.

2. If FAST is negative there are several management options, all of which are acceptable:
 - a. Right-sided thoracoabdominal injuries are acceptable for CT to evaluate the liver, with the understanding that a small laceration to the right diaphragm might not need repair
 - b. Laparoscopy, with or without conversion to laparotomy if the diaphragm is injured. The decision to convert depends on the expertise on the surgeon in both diagnosing and managing injuries laparoscopically.
 - c. If the intent is to repair the diaphragm laparoscopically, observe x 12 hours to rule out hollow viscus injury then evaluate the diaphragm laparoscopically. The period of observation mitigates the concern over a missed hollow viscus injury so that conversion to laparotomy is not necessary if the diaphragm is injured. If the plan is to convert to laparotomy anyway, then it is best to avoid the 12-hr period of observation and approach as described in (2b).